AMERICAN EPILEPSY SOCIETY 2015

December 4 - 8 ■ Philadelphia, PA
69TH ANNUAL MEETING

Spanish Symposium
Frontal Lobe Epilepsy

Symposium Co-Chairs:

Patricio Abad, M.D.

and

Mario A. Alonso-Vanegas, M.D.

Friday, December 4, 2015
Convention Center – Rooom 204 AB

3:30 – 6:00 p.m.

Accreditation

The American Epilepsy Society is accredited by the Accreditation Council for Continuing Medical Education (ACCME) to provide continuing medical education for physicians.

Credit Designation

Physicians

The American Epilepsy Society designates this live activity for a maximum of 30.75 *AMA PRA Category 1 Credits*™. Physicians should claim only the credit commensurate with the extent of their participation in the activity.

Physician Assistant

AAPA accepts certificates of participation for educational activities certified for *AMA PRA Category 1 Credit*™ from organizations accredited by ACCME or a recognized state medical society. Physician assistants may receive a maximum of 30.75 hours of Category 1 credit for completing this program.

Jointly provided by AKH Inc., Advancing Knowledge in Healthcare and the American Epilepsy Society.

Nursing

AKH Inc., Advancing Knowledge in Healthcare is accredited as a provider of continuing nursing education by the American Nurses Credentialing Center's Commission on Accreditation.

This activity is awarded 30.75 contact hours.

Nurse Practitioners

AKH Inc., Advancing Knowledge in Healthcare is accredited by the American Association of Nurse Practitioners as an approved provider of nurse practitioner continuing education. Provider Number: 030803. This program is accredited for 30.75 contact hours which includes 8 hours of pharmacology. Program ID #21547

This program was planned in accordance with AANP CE Standards and Policies and AANP Commercial Support Standards.

Pharmacy

AKH Inc., Advancing Knowledge in Healthcare is accredited by the Accreditation Council for Pharmacy Education as a provider of continuing pharmacy education.

Select portions of this Annual Meeting are approved for pharmacy CE credit. Specific hours of credit for approved presentations and Universal Activity Numbers assigned to those presentations are found in the educational schedules. Criteria for success: nursing and pharmacy credit is based on program attendance and online completion of a program evaluation/assessment.

If you have any questions about this CE activity, please contact AKH Inc. at service@akhcme.com.

International Credits

The American Medical Association has determined that non-U.S. licensed physicians who participate in this CME activity are eligible for *AMA PRA Category 1 Credits*™.

CME/CE Certificates

For those attendees who wish to claim CME or CE, there is an additional fee. Registrants can pay this fee as part of the registration process. Those who do not pre-purchase the credit will also have the ability to pay this fee at the time they attempt to claim credit. Fees for CME increase after January 16 and are a one-time charge per annual meeting.

The evaluation system will remain open through Friday, February 26, 2016. Evaluations must be completed by this date in order to record and receive your CME/CE certificate.

Member Fees:	$50 through January 15, 2016 $75 January 16 – February 26, 2016
Non-member Fees:	$75 through January 15, 2016 $100 January 16 – February 26, 2016

Attendance Certificate/International Attendees

A meeting attendance certificate will be available at the registration desk for international meeting attendees on Tuesday, December 8.

Policy on Commercial Support and Conflict of Interest

The AES maintains a policy on the use of commercial support, which assures that all educational activities sponsored by the AES provide in-depth presentations that are fair, balanced, independent and scientifically rigorous. All faculty, planning committee members, moderators, panel members, editors, and other individuals who are in a position to control content are required to disclose relevant relationships with commercial interests whose products relate to the content of the educational activity. All educational materials are reviewed for fair balance, scientific objectivity and levels of evidence. Disclosure of these relationships to the learners will be made through syllabus materials and the meeting app.

Disclosure of Unlabeled/Unapproved Uses

This educational program may include references to the use of products for indications not approved by the FDA. Faculty have been instructed to disclose to the learners when discussing the off-label, experimental or investigational use of a product. Opinions expressed with regard to unapproved uses of products are solely those of the faculty and are not endorsed by the AES.

OVERVIEW
The symposium will provide an overview of frontal lobe epilepsy, especially the clinical semiology of seizures and the comorbidities associated to intractable cases, with special reference to neuropsychological aspects which affect quality of life including social and psychological development. It will also provide an overview of current practices in Spanish speaking countries to identify intractable cases and refer to surgical management especially in the setting of limited resources.

LEARNING OBJECTIVES
Following participation in this symposium, learners should be able to:

- Recognize clinical semiology and comorbidites of intractable frontal lobe epilepsy
- Evaluate patients with frontal lobe seizures utilizing ictal video-EEG monitoring
- Utilize standard protocols for presurgical planning and surgical management
- Recognize comorbidities of frontal lobe epilepsy. Learners use standarized protocols in neuropsychological assesment and follow-up, to evaluate surgical outcomes

TARGET AUDIENCE
Basic: Those new to epilepsy treatment or whose background in the specialty is limited, e.g., students, residents, general physicians, general neurologists and neurosurgeons, other professionals in epilepsy care, administrators.

Intermediate: Epilepsy fellows, epileptologists, epilepsy neurosurgeons, and other providers with experience in epilepsy care (e.g., advanced practice nurses, nurses, physician assistants), neuropsychologists, psychiatrists, basic and translational researchers.

Agenda
Co-Chairs: Patricio Abad, M.D. and Mario Alonso-Vanegas, M.D.

Introduction
Patricio Abad, M.D.

Semiology of Frontal Lobe Epilepsy
aime Parra, M.D., Ph.D.

Neuropsychological and Behavioral Problems in Frontal Lobe Epilepsy
Andres Kanner, M.D.

Presurgical Evaluation of Frontal Lobe Epilepsy
Daniel San Juan Orta, M.D.

Surgical management of Frontal Epilepsies
Arthur Cukiert, M.D., Ph.D.

Roundtable Discussion
Mario A. Alonso-Vanegas, M.D. and All Faculty

Education Credit
2.5 CME Credits

Nurses may claim up to 2.5 contact hours for this session.

Pharmacy Credit
AKH Inc., Advancing Knowledge in Healthcare approves this knowledge-based activity for 2.5 contact hours (0.25 CEUs). UAN 0077-9999-15-037-L01-P. Initial Release Date: 12/4/2015.

The American Board of Psychiatry and Neurology has reviewed the Frontal Lobe Epilepsy Symposium and has approved this program as part of a comprehensive program, which is mandated by the ABMS as a necessary component of maintenance of certification.

FACULTY/PLANNER DISCLOSURES
It is the policy of the AES to make disclosures of financial relationships of faculty, planners and staff involved in the development of educational content transparent to learners. All faculty participating in continuing medical education activities are expected to disclose to the program audience (1) any real or apparent conflict(s) of interest related to the content of their presentation and (2) discussions of unlabeled or unapproved uses of drugs or medical devices. AES carefully reviews reported conflicts of interest (COI) and resolves those conflicts by having an independent reviewer from the Council on Education validate the content of all presentations for fair balance, scientific objectivity, and the absence of commercial bias. The American Epilepsy Society adheres to the ACCME's Essential Areas and Elements regarding industry support of continuing medical education; disclosure by faculty of commercial relationships, if any, and discussions of unlabeled or unapproved uses will be made.

FACULTY / PLANNER BIO AND DISCLOSURES
Patricio Abad, M.D. (Co-Chair)
Head of Neurology Service, Professor of Neurology, Universidad Católica de Ecuador, Director Epilepsy Center Hospital Metropolitano, Quito-Ecuador

Dr. Abad has indicated he has no financial relationships with commercial interests to disclose.

Mario Alonso-Vanegas, M.D. (Co-Chair)
Mexican neurosurgeon trained in Mexico City and specialized in Epilepsy and Functional Surgery at the Montreal Neurological Institute under the tutelage of Dr. André Olivier. Since January 1999 appointed at the National Institute of Neurology and Neurosurgery in México City, as responsible neurosurgeon for the Advanced Epilepsy Surgery Center and professor of the postgraduate epilepsy surgery course. Member of the ILAE Surgical Therapies Task Force.

Dr. Alonso-Vanegas discloses receiving support for Speakers Bureau from Cyberonics, Inc.

Arthur Cukiert, M.D., Ph.D.
Director, Epilepsy Surgery Program, Clinica de Epilepsia de Sao Paulo, Sao Paulo, Brazil Associate Professor of Neurosurgery, ABC Faculty of Medicine PhD in Human Physiology
Fellow of the Montreal Neurologic Institute

Dr. Cukiert has indicated he has no financial relationships with commercial interests to disclose.

Andres Kanner, M.D.
Dr. Kanner is a Professor of Clinical neurology, Director of the Comprehensive Epilepsy Center and Chief of the Division of Epilepsy in the Department of Neurology at the University of Miami, Miller School of Medicine, which he joined almost three years ago. Dr. Kanner is Editor-in-Chief for Clinical Science of Epilepsy Currents and Chair of the Practice Committee at AES. He has received several awards including the J. Kiffin Penry Award for Clinical Excellence from the AES, Ambassador of Epilepsy Award from the ILAE, the Quito Award from the Latin American Commission of the ILAE. Dr. Kanner's research interest have included pharmacologic, surgical and psychiatric aspects of epilepsy.

Dr. Kanner discloses receiving support for Royalties from Lippinkott, Williams and Wilkins, Wiley Blackwell.

Jaime Parra , M.D., Ph.D.
Medical School in Complutense University, Madrid 84-90, Neurology Residency training in Madrid Spain 90-95, Adjunct attending and Epilepsy and Clinical Neurophysiology fellowship at Rush Presbyterian St Luke´s MC Chicago (95-97), Dutch Epilepsy Clinics Foundations WHO center for Epilepsy 1997-2010; Current positions: Co-director Epilepsy Unit San Rafael Hospital and Epilepsy Unit for refractory cases in La Paz University Hospital , Autonomous University, Madrid, Spain PhD: University of Navarra 2003

Dr. Parra has indicated he has no financial relationships with commercial interests to disclose.

Daniel San Juan Orta, M.D.
ORTA SAN JUAN DANIEL M. D. Neurologist, Clinical Neurophysiologist and Epileptologist.
Head of Department of Clinical Research. National Institute of Neurology and Neurosurgery Manuel Velasco Suarez. Mexico. Associate professor of sub-specialty of Clinical Neurophysiology, UNAM (2008-) and Postgraduate Course High Specialty Epilepsy Surgery Fellowship, UNAM (2009-) and Principal Professor of Neurology General, Medical School, IPN (2010-). Scientific articles published: 25 international and 4 national. Active member of many national and international companies related to neuroscience including coordinator of the Commission of Neurophysiology in Epilepsy of the Mexican branch of ILAE.

Dr. San Juan Orta discloses receiving support for Contract Research from Novartis, Geuber, Medimmune (Principal Investigator); Others Services form Forefront.

CME Reviewer
Leonardo Bonilha, M.D., Ph.D.
I am a neurologist, epileptologist and clinical neurophysiologist. I am an Associate Professor of Neurology at the Medical University of South Carolina, where I work as a clinician scientist. My research involves the mechanistic aspects of brain structure and function (through neuroimaging and EEG) in relationship with language recovery after brain injury, as well as seizures and epilepsy.

Dr. Bonilha discloses receiving support for Consulting from Health Advances, LLC I have provided paid advice regarding best uses of PACS imaging software.

Diego Morita, M.D.
Diego Morita is an Assistant Professor of Pediatrics and Neurology at Cincinnati Children's Hospital Medical Center and the University of Cincinnati College of Medicine. He is the Medical Director of the Cincinnati Children's New Onset Seizure Program and a Co-Medical Director of the Cincinnati Children's Neuroscience Unit. His clinical and research interests are a) quality improvement in healthcare, b) anti-seizure medications side effects, c) health related quality of life.

Dr. Morita discloses receiving support for Contracted Research from UCB (indirect) Eisai (indirect); as Other Service from Epilepsy Foundation of Greater Cincinnati and Columbus: Board of Directors, Professional Advisory Board.

Paul Levisohn, M.D. (Medical Content Specialist, AES)
Dr. Levisohn is a member of the faculty of the section of Pediatric Neurology at The University of Colorado School of Medicine and Children's Hospital Colorado Neuroscience Institute, having joined the faculty over 15 years ago following a similar period of time in the private practice of pediatric neurology. His academic career has focused on clinical care for children with epilepsy with particular

interest in clinical trials and on the psychosocial impact of epilepsy. Dr. Levisohn is currently a consultant on medical content for CME activities to staff of AES. He is a member of the national Advisory Board of EF and has been chair of the advisory committee for the National Center of Project Access through EF.

Dr. Levisohn has indicated he has no financial relationships with commercial interests to disclose.

AKH STAFF / REVIEWERS
Dorothy Caputo, MA, BSN, RN (Lead Nurse Planner) has indicated she has no financial relationships with commercial interests to disclose.

Bernadette Marie Makar, MSN, NP-C, APRN-C (Nurse Planner) has indicated she has no financial relationships with commercial interests to disclose.

John P. Duffy, RPh, B.S. Pharmacy (Pharmacy Reviewer) has indicated he has no financial relationships with commercial interests to disclose.

AKH staff and planners have nothing to disclose.

CLAIMING CREDIT:
PHYSICIANS

Physicians can claim CME credit online at **https://cme.experientevent.com/AES151/**

This Link is NOT Mobile-friendly! You must access it from a laptop, desktop or tablet.

How to Claim CME Credit
To claim CME credits online, please follow the on-screen instructions at the above url. Log in using your last name and zip code, OR your last name and country if you're not from the United States. All CME credits must be claimed **by February 26, 2106**.

Questions?
Contact Experient Customer Service at: 800-974-9769 or **AES@experient-inc.com**

NURSING & PHARMACY

PLEASE NOTE: Providing your NABP e-profile # is required.
The National Association of Boards of Pharmacy (NABP) requires that all pharmacists and pharmacy technicians seeking CE credit have an ID number issued by NABP. Pharmacy CE providers, such as AKH Inc., Advancing Knowledge in Healthcare, are required to submit participant completion information directly to NABP with your ID number and birth information to include month and date (not year) as a validation to this ID number. If you do not have an ID number (this is not your license #), go to: www.MyCPEmonitor.net

Nursing and Pharmacy credit (per session) is based on attendance as well as completion of an online evaluation form available at:

WWW.AKHCME.COM/2015AES

THIS MUST BE DONE BY JANUARY 15, 2016 TO RECEIVE YOUR CE CREDIT.
We cannot submit credit to NABP after this date.
If you have any questions, please contact AKH at service@akhcme.com.

DISCLAIMER

Opinions expressed with regard to unapproved uses of products are solely those of the faculty and are not endorsed by the American Epilepsy Society or any manufacturers of pharmaceuticals.

Semiology of Frontal Lobe Seizures

Jaime Parra M.D., PhD
Epilepsy Units
Hospital San Rafael
Hospital Universitario La Paz
Madrid
Spain

December 4, 2015

Disclosure

Nothing to disclose

Learning Objectives

- Achieve a better understanding of neuronal networks dynamics relevant to the development of the semiology of frontal lobe seizures
- Improve the recognition of signs and symptoms related to frontal lobe seizure semiology and its different subtypes
- Integration of the information provided by seizure semiology in the characterization of the epileptogenic network, the early seizure spread zone and the presurgical work-up of these patients

Impact on Clinical Care and Practice

- Improved recognition of seizure semiology
  - Recognition of characteristic features of frontal lobe seizures and its different subtypes
  - Definition of anatomical structures involved
- Implication for pre-surgical work-up of epilepsy patients
  - More accurate characterization of the epileptogenic zone and early seizure spread zone
  - Integration of the critical information provided by semiology with that from other ancillary methods used in the presurgical evaluation of these patients

Epilepsy is a disorder of distributed neuronal networks

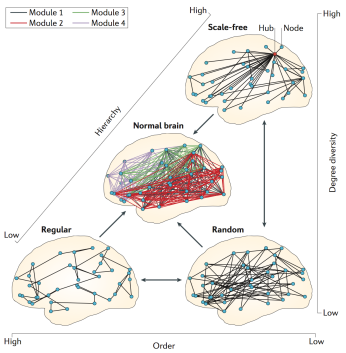

Stam CJ. Modern network science of neurological disorders. *Nat Rev Neurosci*. 2014;15(10): 683-695.

Seizure semiology as a network disorder

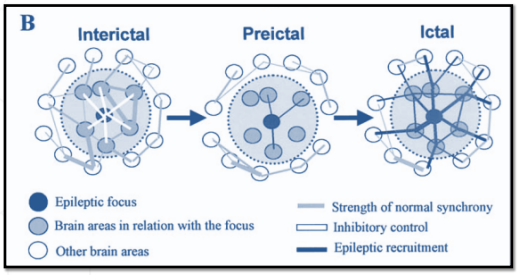

Le Van Quyen M, Navarro V, Martinerie J, et al. Toward a neurodynamical understanding of ictogenesis. Epilepsia 2003;44 Suppl 12:30–43.

New approaches to characterize seizure semiology

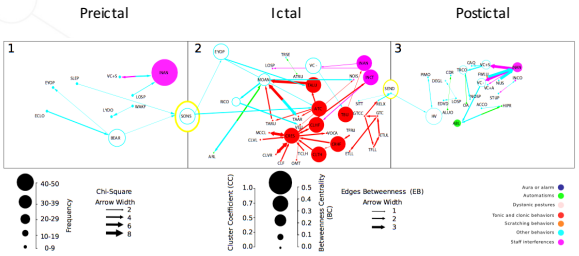

Bertti P, Tejada J, Martins APP, et al. Looking for complexity in quantitative semiology of frontal and temporal lobe seizures using neuroetho and graph theory. *Epilepsy & Behavior.* 2014;38(C):81-93.

Functional organization of frontal lobe

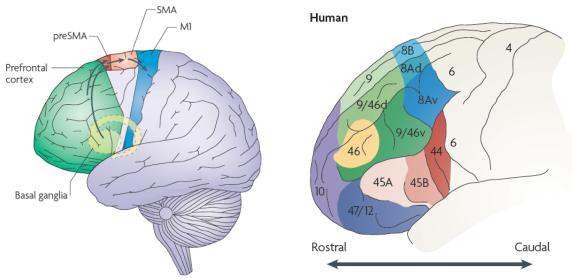

Haggard P. Human volition: towards a neuroscience of will. *Nat Rev Neurosci.* 2008;9(12):934–946.
Badre D, D'Esposito M. Is the rostro-caudal axis of the frontal lobe hierarchical? *Nat Rev Neurosci.* 2009;10(9):659-669.

Schematic anatomical division of the frontal lobe, relevant for seizure semiology

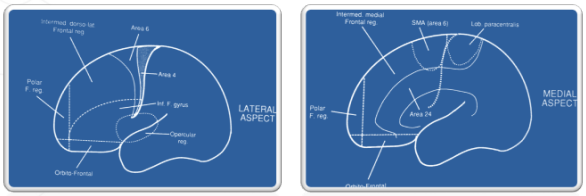

Bancaud J, Talairach J. Clinical semiology of frontal lobe seizures. Advances in neurology; (1992) 57:3-58.

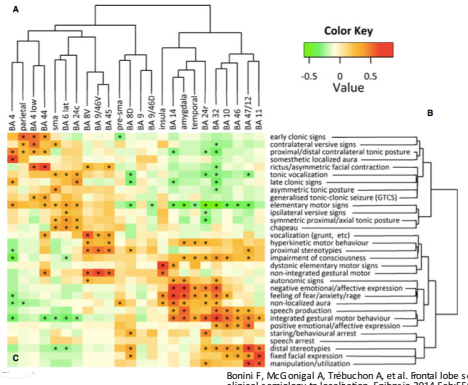

Bonini F, McGonigal A, Trébuchon A, et al. Frontal lobe seizures: from clinical semiology to localization. Epilepsia.2014 Feb;55(2):264–277.

1.-Precentral/premotor areas

- Early clonic signs
- Elementary motor signs
- Contralateral/distal tonic posture
- Somesthetic localized aura
- Contralateral versive signs
- Asymmetric tonic posture
- Tonic vocalization

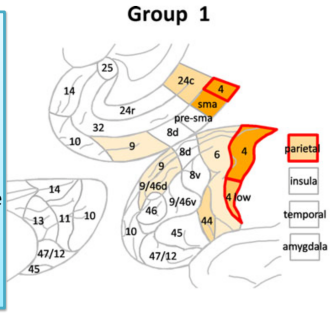

Bonini F, McGonigal A, Trébuchon A, et al. Frontal lobe seizures: from clinical semiology to localization. Epilepsia.2014 Feb;55(2):264–27

Video/example

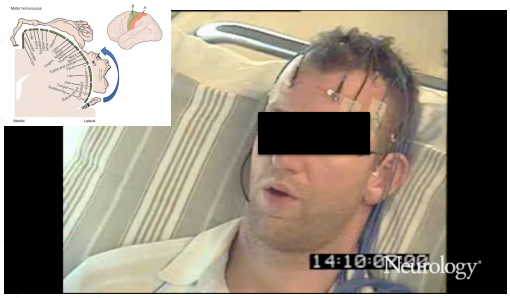

Extercatte J, de Haan GJ, Gaitatzis A. Teaching Video NeuroImages: Frontal opercular seizures with jacksonian march. Neurology. 2015 Mar 16;84(11):e83–e8

2.-Premotor,posterior prefrontal and dorsolateral prefrontal convexity

Group 2

- Symmetric proximal/axial tonic posture
- Non-integrated gestural motor
- Chapeau
- Non-localized aura

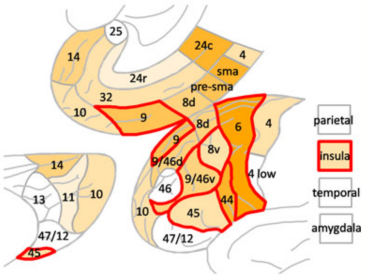

Bonini F, McGonigal A, Trébuchon A, et al. Frontal lobe seizures: from clinical semiology to localization. Epilepsia.2014 Feb;55(2):264–27

AMERICAN EPILEPSY SOCIETY 69TH ANNUAL MEETING

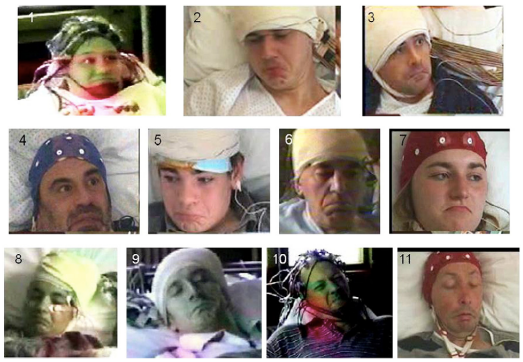

Souirti Z, et al. Neural network underlying ictal pouting ("chapeau de gendarme") in frontal lobe epilepsy. Epilepsy Behav 2014;37:249-57.

AMERICAN EPILEPSY SOCIETY 69TH ANNUAL MEETING

3.-Lateral prefrontal cortex & frontal pole

Group 3

- Proximal& Distal stereotypies
- Fixed facial expression
- Integrated gestural motor behavior
- Manipulation/utilization
- Positive emotional/affective expression
- Impairment of consciousness

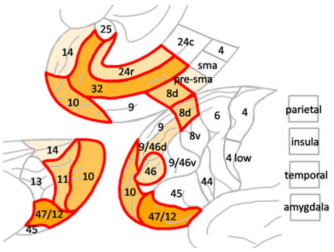

Bonini F, McGonigal A, Trébuchon A, et al. Frontal lobe seizures: from clinical semiology to localization. Epilepsia.2014 Feb;55(2):264–27

AMERICAN EPILEPSY SOCIETY 69TH ANNUAL MEETING

Video/example

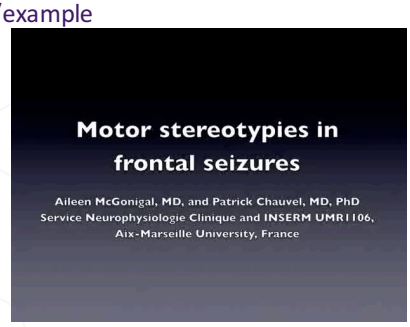

McGonigal A, Chauvel P. Prefrontal seizures manifesting as motor stereotypies. Mov Disord. 2013 Oct 18;29(9):1181–1185.

AMERICAN EPILEPSY SOCIETY 69TH ANNUAL MEETING

4- Ventromedial prefrontal cortex

Group 4

- Negative emotional/affective expression
- Feeling of fear/anxiety/rage
- Speech production
- Integrated gestural behavior
- Autonomic signs
- Nonlocalized aura
- Hyperkinetic motor behavior

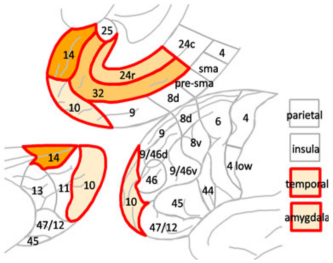

Bonini F, McGonigal A, Trébuchon A, et al. Frontal lobe seizures: from clinical semiology to localization. Epilepsia.2014 Feb;55(2):264–27

AMERICAN EPILEPSY SOCIETY 69TH ANNUAL MEETING

Video/example



Shih JJ, LeslieMazwi T, Fdcao G, Van Gerpen J. DIRECTED AGGRESSIVE BEHAVIOR IN FRONTAL LOBE EPILEPSY: A VIDEO-EEG AND ICTAL SPECT STUDY. Neurology 2009;73(21):1804–1806.

AMERICAN EPILEPSY SOCIETY 69TH ANNUAL MEETING

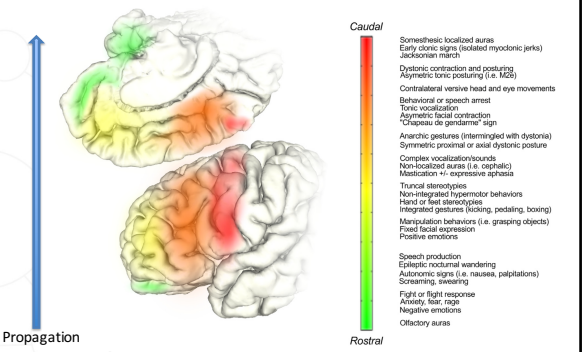

Gibbs S.A., et al. (2015). Sleep-related epileptic behaviors and non-REM-related parasomnias: Insights from stereo-EEG. *Sleep Medicine Reviews*, 1–17.

The mesial frontal lobe

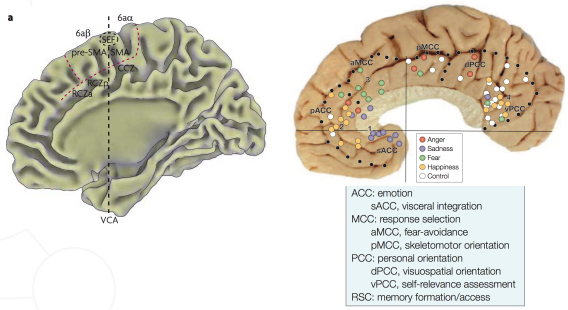

Nachev P, Kennard C, Husain M. Functional role of the supplementary and pre-supplementary motor areas. *Nat Rev Neurosci*. 2008;9(11):856-869.
Vogt BA. Pain and emotion interactions in subregions of the cingulate gyrus. Nat. Rev. Neurosci. 2005;6(7):533-544.

Cingulate Gyrus: Bancaud Type

Patient	Sex	Handedness	Age, y: Onset	Age, y: Evaluation	Lesion	Generalization	Frequency/mo	Aura	Prominent Phase by Video EEG	Other Clinical Features	Resection	Pathology	Outcome (Engel)	Follow-up, y	Medication
Typical Anterior															
1	M	R	12	13		2 during video EEG, none on meds	90	Sensory, fear, freezing, lightheadedness	Hypermotor (twisting around + banging head)	Early loud vocalization	Lesionectomy	Cyst + gliosis	I	1	Yes
2	M	R	2.5	6		None	75	None	Hypermotor (flailing)	Bilateral tonic with R arm extension + ictal urination + personality changes	Lesionectomy	Cortical dysplasia	I	5	No
3	M	R	38	47		None	210	Fear	Hypermotor (flailing)	Early loud vocalization + personality changes	Lesionectomy	Cavernoma	II (total 2 seizures/ 2 y)	2	Yes
4	M	R	32	36		None	105	None	Hypermotor (face distortion + bicycling + flailing +/- running)	Early loud vocalization + mirthless laughter + personality changes	Lesionectomy	Cavernoma	I	9	No
5	F	R	22	25		Rare (Total 5)	120	Fear	Hypermotor (body thrusting + heavy coughing + flailing)	Early loud vocalization + mirthless laughter + postictal behavioral problems	Lesionectomy	Cavernoma	I	2	No
6	M	R	51	51		None	1	None	Hypermotor (violent sweeping arm movements)		Lesionectomy	Meningioma	I	7	No

Alkawadri, R. Et al. (2013). Cingulate Epilepsy. *JAMA Neurology*, *70*(8), 995–8.

Cingulate Gyrus: atypical

Atypical Anterior															
7	F	R	31	32		1/M	105	Freezing	Asymmetric tonic (R arm and leg extension) > R arm clonic		Lesionectomy + adjacent superior frontal gyrus	Low-grade astrocytoma	III (seizure free for 2 y following surgery)	11	Yes
8	F	R	16	24		About 1 in 4	6	None	Sudden stiffening of L arm and oral automatisms	Early loud vocalization	Lesionectomy + adjacent superior frontal gyrus	High-grade astrocytoma	II (seizure free for 2 y following surgery)	1.5	Yes
9	F	R	1	4		Rare	9	None	Head and eyes forced tonic deviation to the R		Lesionectomy + adjacent superior frontal gyrus	Low-grade astrocytoma	I	4	No
10	M	R	45	49		About 1 in 2	30	None	Hypermotor + automatisms (R hand) or generalized myoclonic jerk	Early loud vocalization + ictal urination	Lesionectomy	Low-grade astrocytoma	III (seizure free for 2 y following surgery)	3	Yes

Alkawadri, R. Et al. (2013). Cingulate Epilepsy. *JAMA Neurology*, *70*(8), 995–8.

Video/example

Nuria Lacuey, Javier Chapa Davila, Bilal Zonjy, Shahram Amina, Marta Couce, John Turnbull, Jonathan Miller, Hans Lüders, Sam den D Lhatoo. Lesion-negative anterior cingulate epilepsy (WITH VIDEO). Epileptic Disorders. 2015;17(2):134-142. doi:10.1684/epd.2015.0749

Maria Paola Canevini, Laura Tassi, Lucia Fusco, Anna Teresa Giallonardo, Renzo Guerrini, Roberto Mai, Guido Rubboli, Paolo Tinuper, Federico Vigevano. Frontal lobe seizures. Epileptic Disorders. 2002;3(4):223-4.

Frontal lobes & Consciousness

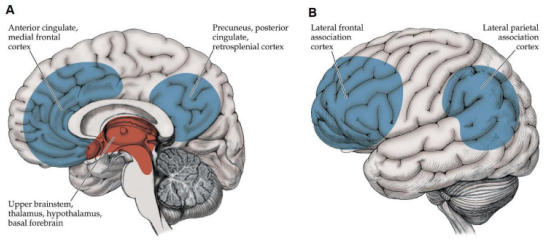

Blumenfeld P.H. Impaired consciousness in epilepsy. Lancet Neurol 2012;11(9):814–826.

Loss of Consciousness in frontal lobe seizures

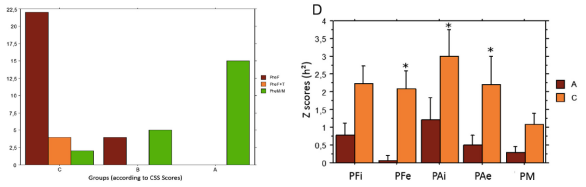

Bonini, F., et al. (2015). Altered synchrony and loss of consciousness during frontal lobe seizures. *Clinical Neurophysiology*, 1–6.

Secondary generalization in frontal lobe seizures

Frontal Lobe Epilepsy Risk Stratification

Table 2. Semiologic predictors of SGTCS in FLE

	With SGTCS ($n = 32$) (%)	Without SGTCS ($n = 16$) (%)	p-Value Univariate	p-Value Multivariate
Semiology clusters				
Elementary motor signs	14 (44)	2 (13)		
Complex posturing	10 (31)	4 (25)	**0.02**	**0.01**
Gestural behaviors	8 (25)	6 (38)		
Psychomotor agitation	0 (0)	3 (19)		
Individual signs				
Nocturnal FLE	11 (34)	6 (38)	NS	–
Early responsiveness	10 (31)	10 (63)	**0.04**	**0.04**
Individual signs included in cluster				
Version	25 (78)	4 (25)	–	–
Ictal cry	8 (25)	0 (0)	–	–
Asymmetric tonic–clonic signs	13 (41)	3 (19)	–	–
Asymmetric facial contraction	4 (13)	2 (13)	–	–
Atonic signs	11 (34)	1 (6)	–	–
Bilateral tonic posturing	13 (41)	3 (19)	–	–
Proximal/axial automatism	6 (19)	9 (56)	–	–
Distal automatism	8 (25)	5 (31)	–	–
Manipulation/utilization	3 (9)	4 (25)	–	–
Vocalization (grunts)	6 (19)	5 (31)	–	–
Oral automatism	1 (3)	4 (25)	–	–
Symmetric facial contractions	3 (9)	3 (19)	–	–
Fixed facial expression	9 (28)	6 (38)	–	–
Hypermotricity	2 (6)	4 (25)	–	–
Negative emotions	3 (9)	4 (25)	–	–
Autonomic signs	6 (19)	5 (31)	–	–

Asym: Asymetric; Prox: proximal; NS: not significant; – not included in statistical testing.
Semiologic clusters and their constituent signs (Nocturnal FLE and early responsiveness are not included in semiologic clusters). Final multivariate analysis included semiology clusters and early responsiveness (in bold).

Baud, M. O., Vulliemoz, S., & Seeck, M. (2015). Recurrent secondary generalization in frontal lobe epilepsy: Predictors and potential li to surgical outcome? *Epilepsia*, *56*(9), n/a–n/a. http://doi.org/10.1111/epi.13086

Conclusions

1. Semiologic features in frontal lobe seizures (FLS) depend neither the anatomical origin of the ictal discharge nor the target areas of its propagation alone but on the dynamic interaction between both of them and are highly reproducible in an individual patient.
2. Semiology of FLS follows a propagation of the ictal discharge in a rostral to caudal axis. No organization is clarified for the mesial-lateral axis. . yet
1. Clinical semiology localizes the epileptogenic phenomenon as it is and it offers essential information as to the full characterization of the epileptogenic network generating the seizures.

#AESmtg15

AMERICAN EPILEPSY SOCIETY

69TH ANNUAL MEETING DECEMBER 4 - 8, 2015 PHILADELPHIA, PA

Psychiatric and Neurospychological Aspects of Frontal Lobe Epilepsy: What do we know and what is left to investigate?

Andres M. Kanner, MD
Professor of Clinical Neurology,
Head, Division of Epilepsy and
Director, Comprehensive Epilepsy Center,
University of Miami, Miller School of Medicine, Miami, FL.

MILLER SCHOOL OF MEDICINE UNIVERSITY OF MIAMI

December 4, 2015

AMERICAN EPILEPSY SOCIETY 69TH ANNUAL MEETING DECEMBER 4 - 8, 2015 PHILADELPHIA, PA

Disclosure

None

AMERICAN EPILEPSY SOCIETY 69TH ANNUAL MEETING

Learning Objectives

- The purpose of this presentation is to review:
- Role of the frontal lobe in cognitive functions.
- Role of the frontal lobe on mood and anxiety disorders.
- Psychiatric and cognitive deficits associated with frontal lobe damage.
- Cognitive disturbances in frontal lobe epilepsy.
- Psychiatric disturbances in frontal lobe epilepsy.
- Cognitive and psychiatric complications of epilepsy surgery.

AMERICAN EPILEPSY SOCIETY 69TH ANNUAL MEETING

Impact on Clinical Care and Practice

- Recognize the cognitive functions mediated by the frontal lobe
  - Cognitive disturbances in frontal lobe damage
  - Cognitive disturbances in frontal lobe epilepsy
  - Cognitive complications of frontal lobectomy
- Recognize the role of the frontal lobe in mood and anxiety disorders
  - Mood and anxiety disorders in frontal lobe epilepsy
  - Psychiatric complications of frontal lobe epilepsy

AMERICAN EPILEPSY SOCIETY 69TH ANNUAL MEETING

Phineas Gage

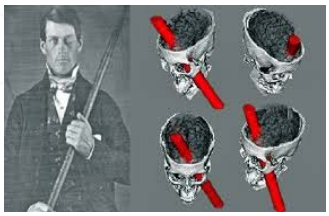

AMERICAN EPILEPSY SOCIETY 69TH ANNUAL MEETING

Phineas Gage

- Railroad foreman who suffered severe bilateral frontal lobe damage caused by iron rod in an explosion.
- No functional impairment in activities of daily living.
- Change in personality:
  - Irresponsible
  - "Convention-neglecting person"

Frontal lobes and cognition

Shulman AB, Epilepsy & Behavior, 2001

- Frontal lobe networks are responsible for *executive processes*:
  - Focusing attention on relevant information and inhibiting irrelevant information.
  - Switching focused attention between tasks.
  - Planning a sequence of subtasks to accomplish a goal.
  - Monitoring and updating the contents of working memory to determine the next step in a sequential task.
  - Coding representations in working memory for time and place of appearance

Cognitive and behavioral functions mediated by frontal lobe structures

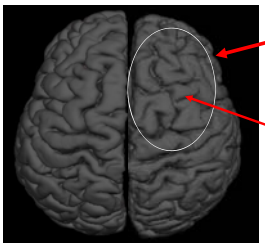

Prefrontal Cortex
- Working memory
- Incentive judgment
- Personality

Dorso-lateral cortex
- Abstract thinking
- Problem solving
- Reasoning

Cognitive and behavioral functions mediated by frontal lobe structures

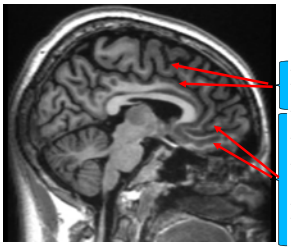

Prefrontal Cortex
- Motivation
- Affective behavior and regulation
- Humor appreciation

- Inhibitive control of behavior
- Appreciation of consequence of actions
- Interpersonal behavior
- Perception of emotions

Cognitive functions tested in neuropsychological evaluations

- Reasoning
- Concept formation
- Cognitive flexibility
- Learning from errors
- Planning
- Problem solving
- Psychomotor speed
- Selective attention
- Sustained attention
- Auditory divided attention
- Vigilance
- Ability to sustain task effort
- Practical judgment

Changes Resulting from Frontal Lobe Damage

Eslinger et al., Brain & Cognition, 2004

- N = 10 patients with frontal lobe lesions at infancy or childhood
- Age at lesion onset: Perinatal to age 12
- Side of lesion:
  - Right: 4
  - Left: 2
  - Bilateral: 4

Changes Resulting from Frontal Lobe Damage

Eslinger et al., Brain & Cognition, 2004

Patient # and side / age	Cognitive profile (IQ)	Behavioral disturbances
1 / bilateral 12 y.o.	92	- cannot sustain friendships - poor planning, impulse control - poor learning from experiences
2/ bilateral 28 y.o.	96 (V = 102 P= 90)	- cannot sustain friendships - poor planning, impulse control - poor learning from experiences - criminal behavior
3/ bilateral 20 y.o.	90 (V = 85 P = 98)	- criminal behavior - lack of empathy - impulsive, disruptive behavior
4/ bilateral 24 y.o.	78 (V = 78 P = 83)	- impulsive and physical assaults - planning, poor judgment - poor learning from experiences

Changes Resulting from Frontal Lobe Damage

Eslinger et al., Brain & Cognition, 2004

Patient # and side /age	Cognitive profile (IQ)	Behavioral disturbances
• 1 / right 23 y.o.	• 98 (V = 94 (P = 104)	- Inattentive, impulsive - poor judgment, no fear, no anxiety - no empathy, poor social relations
• 2/ right 16 y.o.	• 95	- cannot sustain friendships - poor impulse control and disinhibition - minimal sensitivity to emotional state of others
• 3/ right 6 y.o	• 128 (V = 119; P = 132)	- difficulty learning from experience - poor self-regulation in complex social environments - impulsive, poor frustration tolerance
• 4/ right 16 y.o.	• 101-121 (V = 112-125)	– Social problems - Impulsive

Neuropsychological deficits in patients with frontal lobe epilepsy

- Compared to healthy controls, patients with frontal lobe epilepsy have been found to exhibit deficits in tests evaluating:
  - Social cognition
  - Mental flexibility
  - Rapid visual motor coordination
  - Interference and response inhibition
  - Anticipation and planning
  - Verbal and non-verbal fluency
  - Concept formation
  - Motor sequencing and motor coordination

Neuropsychological deficits in patients with frontal lobe epilepsy

- Frontal lobe epilepsy *does not*:
  - affect IQ
  - have a different impact on verbal and visual mediated functions relative to the side of the epileptogenic area (in contrast to temporal lobe epilepsy)
  - the neuropsychological deficits do not correlate with age of onset, duration of seizure disorder and severity of seizures in all studies,

Frontal lobe cognitive abnormalities in other types of epilepsy

- In temporal lobe epilepsy
  - particularly when associated with depressive disorders.
- In juvenile myoclonic epilepsy

Executive functions abnormalities

- In patients with:
  - Frontal lobe epilepsy
    - - before and following frontal lobe resections.
- Laterality of seizure focus remains a source of debate.
- Depressive disorders with and without epilepsy and with temporal and extra-temporal foci.

Relation between depression and executive functions

Dulay et al., Epilepsy & Behavior 2013

- N = 64 patients with frontal lobe epilepsy who underwent a left frontal resection.
- With symptoms of depression: n = 16
- Patients with pre-surgical symptoms of depression performed worst before and after surgery in several measures of EF, measured with:
  - Wisconsin card sorting test
  - Trail Making test
  - Letter fluency

Role of prefrontal cortex in psychiatric disorders

- ❑ Mood disorders
- ❑ Anxiety disorders
- ❑ Addiction disorders
- ❑ Attention deficit hyperactivity disorders

➢ Result from disruption of limbic circuit that include temporal and subcortical structures.

Multifactorial etiology of interictal behavior in frontal and temporal lobe epilepsy

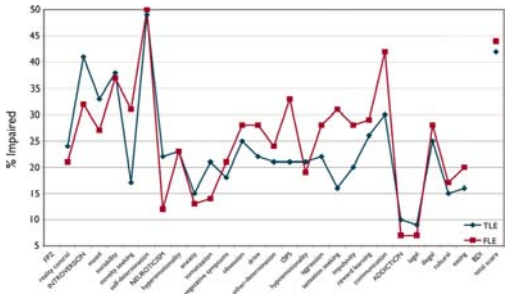

Type of Psychiatric Comorbidities in Frontal Lobe Epilepsy

❖ ADHD

➢ Impulsive behavior / poor frustration tolerance

➢ Problems with attention

➢ Difficulty with decision making process

❖ Mood disorders

❖ Anxiety disorders

Cognitive and psychiatric complications after frontal lobe epilepsy…

Postsurgical psychiatric complications can be the expression of:

- ❑ A *de-novo* psychiatric disorder.
- ❑ A *recurrence* of psychiatric disorder that had been in remission for a period of time prior to surgery.
- ❑ An *exacerbation* in severity of a psychiatric disorder that was present in a sub-clinical form or that was mild enough in severity that had gone unrecognized by patient, family and clinician or that was identified because of a more careful evaluation of the patient.

What do we know?

- ***Nothing!***

What is left to investigate?

Everything!!!

What accounts for the lack of data in epilepsy surgery of the frontal lobe?

- There are no complications?
- It has not been investigated?
- Both?

The most frequent postsurgical psychiatric complications include:

1. Depressive and anxiety disorders
2. Psychotic disorders.
3. Psychogenic non-epileptic events (PNEE) and other types of somatoform disorders.

Post-surgical psychiatric complications

Wrench et al., Epilepsia 2011

- 62 patients who underwent epilepsy surgery
- 43 had an antero-temporal lobectomy
- 19 had an extratemporal lobectomy (n = 17 FLE)

Presurgical Psychiatric comorbidity:

- ***ATL:***
  - Depressive disorder: 33% ATL
  - Anxiety disorder: 23% respectively
- ***Frontal lobectomy:***
  - Depression: 53%
  - Anxiety disorder: 18%

Post-surgical Psychiatric complications:
Depressive /Anxiety disorder

At one month

- ***ATL***
  - 66%
  - De-Novo: 0%
- ***Frontal lobectomy:***
  - 19%

At 3 months

- ***ATL:***
  - 54%
  - De-Novo:
    - Depression: 15%
    - Anxiety: 13%
    - Other: 18%
- ***Frontal lobectomy:***
  - 33%
  - De-novo:
    - Anxiety: 17%

Mood Disturbance before and after Seizure Surgery: A Comparison of Temporal and Extratemporal Resections

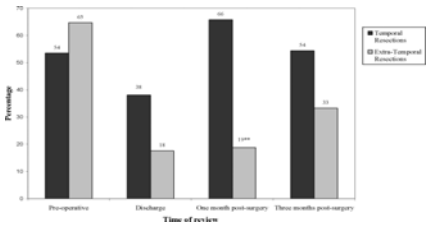

Epilepsia; Volume 45, Issue 5, pages 534-543, 14 MAY 2004

Anxiety Disturbance before and after Seizure Surgery: A Comparison of Temporal and Extratemporal Resections

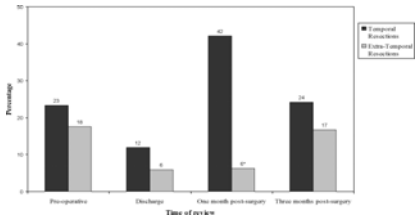

Epilepsia, Volume 45, Issue 5, pages 534-543, 14 MAY 2004

De-Novo Mood and Anxiety Disturbance after Seizure Surgery: A Comparison of Temporal and Extratemporal Resections

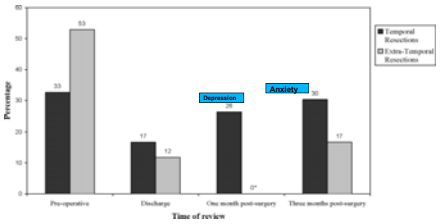

Epilepsia. Volume 45, Issue 5, pages 534-543, 14 MAY 2004

Fig.1 A. Performance in the KSP scales pre- and two years postoperatively. The x-axis shows the KSP scales, and the y-axis illustrates the pre- and postoperative T-score means and standard deviation (SD) in the TLE and FLE groups. T50 represents the mean

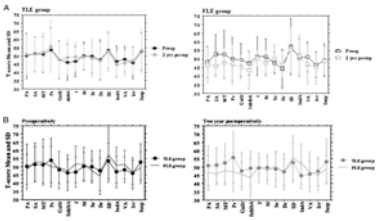

Elisabeth Engman , Kristina Malmgren

A longitudinal study of psychological features in patients before and two years after epilepsy surgery

Epilepsy & Behavior Volume 24, Issue 2 2012 221 - 226

Psychiatric complications of frontal lobe epilepsy surgery

Kanner et al., unpublished data

- N = 11
- Gender: male, n = 6 / female, n = 5
- Mean age: 38.6±7 years old
- Pre-surgical psychiatric history: n = 4 (38%)
- Post-surgical complications: n = 6/11

Psychiatric complications of frontal lobe epilepsy surgery

Kanner et al., unpublished data

- N = 11
- Psychiatric complications: n = 6
- Type of psychiatric complications at 6 months:
  - Abulia / apathy: n = 3+
  - Depression: n = 3*
  - Worsening cognitive functions: n = 1*
  - De-novo, n = 3

• + all 3 patients with abulia had an IQ in the borderline range

Variables involved in post-surgical psychiatric disturbances:

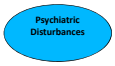

Variables involved in post-surgical psychiatric disturbances:

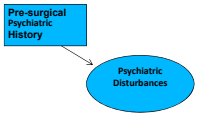

Variables involved in post-surgical psychiatric disturbances:

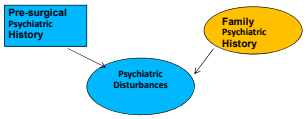

Variables involved in post-surgical psychiatric disturbances:

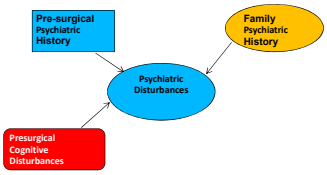

Variables involved in post-surgical psychiatric disturbances:

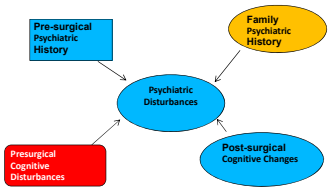

Variables involved in post-surgical psychiatric disturbances:

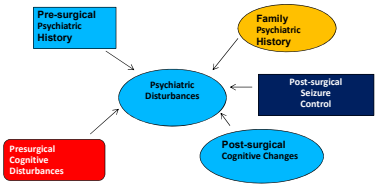

Proposed Protocol: Pre-surgical Evaluation

- *Psychiatric evaluation:*
  - Mini Neuropsychiatric Interview: Categorical Diagnosis (DSM-IV-TR)
  - Family Psychiatric Questionnaire
  - Beck-Depression Inventory (Severity of symptoms of depression)
  - Generalized Anxiety Disorder-7 (Severity of symptoms of anxiety).
- ***Neuropsychological evaluation***

Proposed Protocol: Post-surgical Evaluation

- *Psychiatric evaluation:*
  - Mini Neuropsychiatric Interview: Categorical Diagnosis (DSM-IV-TR)
  - Beck-Depression Inventory (Severity of symptoms of depression)
  - Generalized Anxiety Disorder-7 (Severity of symptoms of anxiety).
- ***Neuropsychological evaluation***

Conclusions

1) Psychiatric comorbidities and cognitive disturbances comorbidities are relatively common in patients with frontal lobe epilepsy.
2) While frontal lobe epilepsy may be associated with characteristic cognitive disturbances, these my also be identified in patients with other types of epilepsy.
3) Psychiatric comorbidities are not specific to frontal lobe epilepsy.
4) Post-surgical psychiatric comorbidities are common in temporal lobe epilepsy surgery, but remain unknown in frontal lobe epilepsy surgery.
5) Psychiatric evaluations need to be incorporated in pre and post-surgical evaluations of patients who undergo frontal lobectomies.



Evaluación Pre-quirúrgica de la Epilepsia del Lóbulo Frontal

Daniel San juan Orta, M.D.
Instituto Nacional de Neurología y Neurocirugía
Manuel Velasco Suárez, Distrito Federal, México.

4 Diciembre 2015

Conflictos de Intereses

Investigador Principal en Clinical Research Institute de estudios clínicos de Novartis, Geuber y MedInmmune.

Neurofisiólogo Clínico de Fofefront, S.A. de C.V.

Objetivos de Aprendizaje

- Describir la evaluación pre-quirúrgica de la epilepsia del lóbulo frontal
- Retos en la evaluación pre-quirúrgica de la epilepsia del lóbulo frontal
- Experiencia personal utilizando el proceso.

Impacto en la Práctica Clínica y Práctica

- La ELF afecta a 600,000 personas en USA.[1]
- Las crisis epilépticas del lóbulo frontal constituyen el 20-30% de todas las epilepsias parciales, ocupando el 2do lugar.[2]
- La ELF puede ser confundidas con eventos no epilépticos, tales como psicogénicos, desordenes del movimiento y parasomnias.[3]

[1]Delgado-Escuela AV, 1992; [2]Forcadas-Berdusán MI, 2002; [3]Lee R et al., 2012

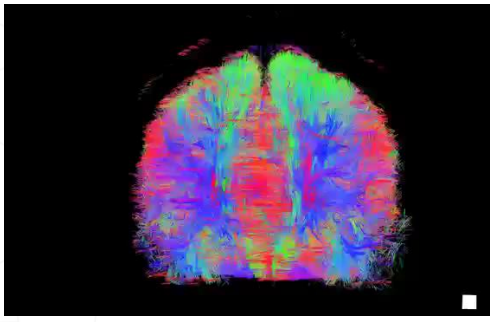

https://www.youtube.com/watch?v=tLoEHeC5n80

Pronóstico de la cirugía de epilepsia

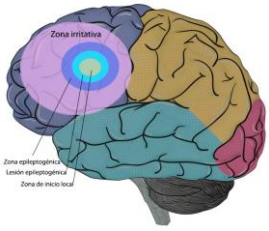

El éxito de la cirugía de epilepsia depende de la adecuada localización y la completa remoción de la zona epileptogénica[1]

[1]Epilepsia. 2000;41(Suppl. 3):S55–S60

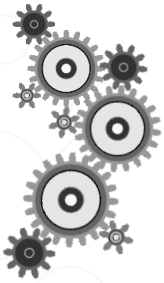

Fase No Invasiva

Es vital la historia clínica

"The Doctor", Luke Fildes

Evaluación diagnóstica

EEG	VIDEO-EEG	TC	RM (1.5 a 3.0T)	PET
SPECT	fMRI	MRS	iECoG	EEG subdural
EEG-fMRI	RM 7.0 T	WADA	Psicología	MEG
	SEEG	PET-MRI	ESI	

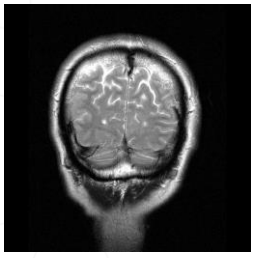

Neuroimagen

Evaluación neuro-radiológica de la ELF

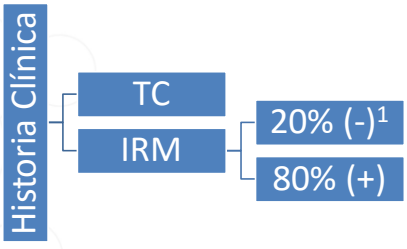

[1]McGonigal A & Chauvel P, Practical Neurology, 2004, 4, 260–273

Evaluación neuro-radiológica de la ELF

No existe un consenso acerca de un protocolo específico de IRM o secuencias[1]

Secuencias

- Eco de gradiente potenciada en T1 (P. ej en GE la secuencia SPGR [Spoiled Gradient Echo]).
- T2 axial y coronal.
- FLAIR (Fluid attenuated inversion recovery) axial y coronal.
- T2 de alta resolución (fast o turbo spin eco).
- Grosor máximo no > 4-5 mm, recomendado (2 o 3 mm) o adquisiciones volumétricas en 3D con un grosor de 1-2 mm.
- *Gadolinio* para casos seleccionados (P. ej tumor, MAVs).
- ¿Transferencia de magnetización?
- Imagen basada en el tensor de difusión.
- Espectroscopia.
- fRMI (Resonancia magnética funcional).

[1]Gaillard W et al., Epilepsia, 50(9):2147–2153, 2009

Evaluación neuro-radiológica de la ELF

❖ Otras secuencias que se pueden utilizar en ELF son:

- T1 inversión recuperación
- STIR axial y coronal
- Difusión
- T2*
- 3D TOF

<2 años de edad

- Secuencias T1 ponderadas; sagital, axial y coronal.
- T2 de alta resolución

[1]Gaillard W et al., Epilepsia, 50(9):2147–2153, 2009

Displasia cortical focal

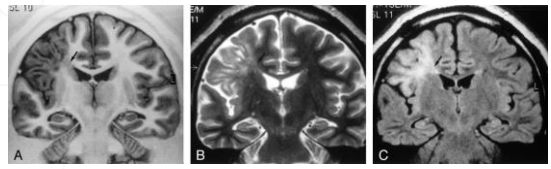

RM de DCF de Taylor con células en balón. **A)**. Secuencia turbo coronal ponderada en T1 -SE IR (3000/20/400/2) que demuestra engrosamiento de la corteza frontal derecha con pérdida de demarcación entre la materia gris y blanca y disminución de la intensidad de seña de la sustancia blanca (flecha) hacia el ventrículo. **B)** Imagen potenciada en T2 turbo coronal SE (2300/100/4) y **C)** ponderada en T2 turbo coronal SE FLAIR (6000/100/2000/3), en el mismo nivel de A, que muestran una mayor intensidad de la señal (flecha) de la sustancia blanca subcortical que se extiende hasta el ventrículo como una banda radial. Sin efecto de masa.

Nadia Colombo et al. AJNR Am J Neuroradiol 2003;24:724-733

Displasia cortical focal

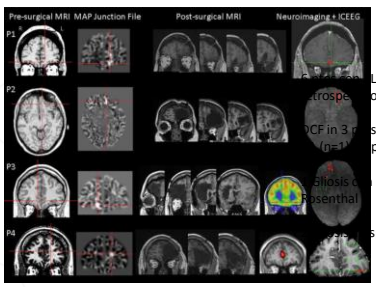

LF orbito-frontal,
o
s, con DCF tipo
po IA (n=2)
fibras de
specífica

Cuatro de los pacientes con epilepsia con hallazgos MAP (morphometric analysis program) positivos que aparecen en el archivo de la unión gris-blanca. 1ra columna : imagen potenciada en T1 pre - quirúrgica ; 2da columna: archivo unión MAPA coregistradas ; 3era columna : MRI post-quirúrgica que indica la resección de la DE región. Las cruces rojas muestran la ubicación de las anomalías sutiles . El resto de la columna (s) contiene ilustraciones de EEG intracraneal (ICEEG). Contactos de electrodos rojos indican el inicio ictal durante la monitorización invasiva.

[1]Wang ZI et al., Epilepsia. 2013 Dec;54(12):2195-203

SPECT/PET: Evalúan función y metabolismo

Radiotrazadores Clínicos:

❖ PET ^{18}F-FDG (Metabolismo cerebral regional)

❖ SPECT ^{99m}Tc-ECD, ^{99m}Tc-HMPAO (Perfusión cerebral regional)

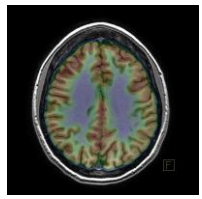

Cortesía Dr. Iván Díaz M. Imagen archivo Unidad de Imagen Molecular PET/CT; INNN

Objetivo: Localización pre-quirúrgica no invasiva de la zona epileptogénica[1]

NO aporta información diagnóstica en caso de RM lesional concordante con la semiología y neurofisiología[1]

[1]Semin Nucl Med 2008 38:227-239

SPECT/PET: Evalúan función y metabolismo

Radiotrazadores Experimentales:

TABLE 1
Targeted Pathways, Used Radiotracers, and Their Usual Uptake Pattern in Epileptogenic Region

Target	Used radiotracers	Uptake pattern in epileptogenic region
Blood perfusion	^{15}O-H_2O, ^{99m}Tc-ethyl cysteinate dimer, ^{99m}Tc-hexamethyl propyleneamine oxime	Interictal decrease; ictal increase
Metabolic pathways		
Glucose metabolism	^{18}F-FDG	Interictal decrease*; ictal increase
Serotonin/kynurenine metabolism	^{11}C-α-methyl-L-tryptophan	Interictal increase
Dopamine synthesis	^{18}F-L-DOPA†	Interictal decrease
Monoamine oxidase	^{11}C-deuterium-deprenyl‡	Interictal increase
Receptors		
Benzodiazepine	^{11}C-flumazenil§	
Opiate	^{11}C-carfentanil‖, ^{18}F-cyclofoxy¶, ^{11}C-diprenorphine#, ^{11}C-methylnaltrindole**	Interictal increase; interictal decrease
5-hydroxytryptamine	^{18}F-FCWAY††, ^{11}C-WAY††, ^{18}F-AFPR‡‡	Interictal decrease
Dopamine	^{18}F-fallypride§§, ^{11}C-SCH23390‖‖	Interictal decrease
Peripheral benzodiazepine or translocator protein	^{11}C-PK11195¶¶, ^{11}C-PBR28##	Interictal increase
Histamine	^{11}C-doxepin***	Interictal increase
N-methyl-d-aspartic acid	^{11}C-ketamine†††	Interictal decrease
Acetylcholine	^{18}F-FA85380‡‡‡	Interictal decrease

J Nucl Med 2013; 54:1775–1781

Indicaciones de SPECT/PET en ELF

❖ IRM (-) con datos electrofisiológicos y clínicos discordantes
❖ IRM con >1 lesión
❖ IRM lesional con datos electrofisiológicos y clínicos discordantes
❖ Identificación de corteza epileptógénica no resecada[1-3]

SPECT ictal > ó = PET interictal >> SPECT interictal

PET mayor resolución espacial que SPECT permite una mejor valoración de la corteza cerebral (3-5 mm)

Semin Nucl Med;2008 38:227-239 J Nucl Med 2013; 54:1924–1930 J Nucl Med 2013; 54:1775–1781

Utilidad de SPECT/PET en ELF

- 30-43% SPECT ictales localizan la zona ictal en adultos.[1]
- 75% FDG-PET tienen hipometabolismo unilateral con RM anormal[2]
- 29-45% FDG-PET tienen hipometabolismo unilateral RM normal [3]
- Sensibilidad de PET en ELF va del 45 a 92%[4]
- El PET proveer información adicional >2/3 partes de los ptes impactado en el tratamiento en 50-70%[4]

[1]Lee Sk et al. Neuroradiology 2006;48:678–84; [2]Ryvlin P, et al., Brain 1998;121:2067–81; [3]Hamer HM et al., Neurology 2002;58:97–103; 4 Gaillard WD et al., Neurology.2002;58:717–722.





Cortesía Dr. Iván Díaz M. Imagen archivo
Unidad de Imagen Molecular PET/CT; INNN



Cortesía Dr. Iván Díaz M. Imagen archivo
Unidad de Imagen Molecular PET/CT; INNN

La efectividad clínica y costo efectividad de las tecnologías usadas para visualizar el foco epiléptico en personas con epilepsia refractaria siendo considerados para cirugía de epilepsia.

Dieciocho estudios (1,312 participantes; rango 24 a 469)
- 13 Exactitud diagnóstica,
- 7 Predictivos de resultados (3 ambos) y
- 1 Impacto de los resultados en la toma de decisiones.

✓ El estudio de PET-FDG decidió la cirugía o no en 70/110 ptes.

Estrategia: 1er PET-FDG con EEG invasivo sin decisión, fue más costo-efectiva, umbral £20,000 a £30,000 (2010) por calidad ajustada de años de vida ganados.[1]

[1]Bursch J et al., Health Technol Assess 2012; 16(34): 1-163.

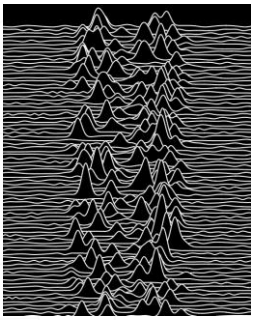

Neurofisiología Clínica

Evaluación neurofisiológica de la ELF

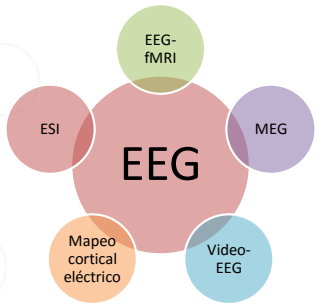

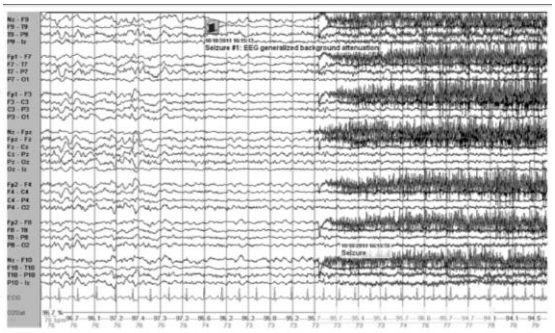

Fig. 1. Crisis del lóbulo frontal con un electroencefalograma (EEG) de superficie no localizador. Mujer de 34 años con crisis nocturnas caracterizadas por vocalización estereotípica. El EEG mostró un inicio de atenuación generalizada de la actividad de fondo seguida de actividad muscular. La resonancia magnética de cráneo mostró una displasia cortical en la región frontal derecha que fue confirmada en el SISCOM.

EEG Interictal: 40% No detecta actividad epileptiforme[2,3]

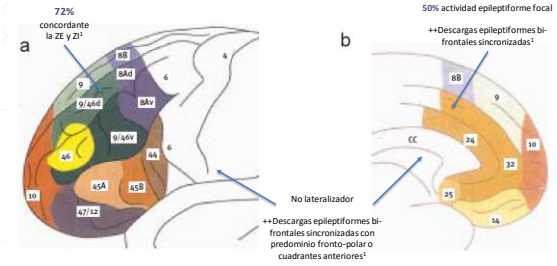

Figura 1. Diagrama cito-arquitéctonico del lóbulo frontal (corte.za prefrontal mostrada en color) con áreas de Broadmann (Petrides & Pandya, 1994) a) Vista lateral, b) Vista medial. Reimpreso de *The Frontal Lobes, Computational Modelling and Neuropsychology: Handbook of Neuropsychology*, Vol 9, Boller F, Spinnler H, Hendler JA, 1994, con permiso de Elsevier [1]McGonigal A & Chauvel P, Practical Neurology, 2004, 4, 260–273; [2]Bautista et al., 1998; [3]Salanova et al., 1993

EEG Ictal

Dorsolateral: 65% concordante la ZE[1]

36% Actividad epileptiforme repetitiva
26% Delta rítmico
14% Supresión
9% Theta rítmico

VPN 93% vs mesial[2]

Mesial: EEG con artefactos
25% Lateralizados[1]

33% Actividad rápida
29% electroedecremento

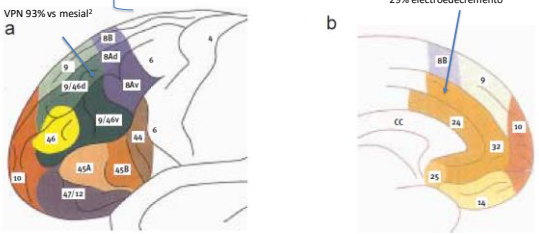

La actividad focal ictal en frecuencia β predice un resultado excelente en cirugía de epilepsia lesional y no lesional.[3]

Figura 1. Diagrama cito-arquitéctonico del lóbulo frontal (corteza prefrontal mostrada en color) con áreas de Broadmann (Petrides & Pandya, 1994) a) Vista lateral, b) Vista medial. Reimpreso de *The Frontal Lobes, Computational Modelling and Neuropsychology: Handbook of Neuropsychology*, Vol 9, Boller F, Spinnler H, Hendler JA, 1994, con permiso de Elsevier [1]McGonigal A & Chauvel P, Practical Neurology, 2004, 4, 260–273; [2]Bautista et al., 1998; [3]Worrell et al., 2002

MEG y ELF

https://www.youtube.com/watch?v=Ko5ZUXr0yMg

MEG y ELF

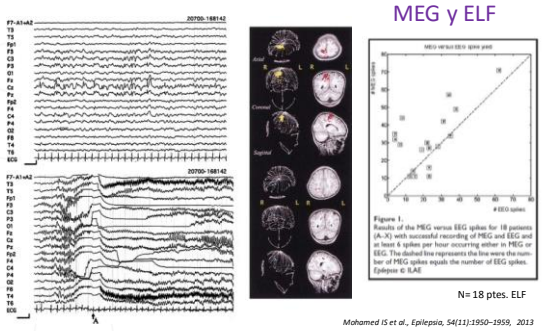

N= 18 ptes. ELF

Mohamed IS et al., Epilepsia, 54(11):1950–1959, 2013

Figura 1. EEG del paciente 1. Arriba, izquierda: puntas en Cz en el EEG . Abajo a la izquierda: A la hora indicada por la flecha A , el paciente tuvó un ataque habitual . Ritmos agudos difuso bilaterales se observan antes de la crisis , que se suprimen al inicio de la crisis , y van seguidos por un ritmo de puntas dominante anterior en Cz. Arriba : a la derecha : Los dipolos actuales equivalentes (ECDs) derivado de las putas interictales magnetoencefalografía interictal (MEG) (puntos amarillos y rojos) se agrupan alrededor del área motora suplementaria derecha (SMA) . Abajo , derecha: ECD derivados de las puntas que ocurren en MEG inicio ictal (azul y puntos rojos) también se localiza alrededor de la SMA derecho

Requerimientos mínimos

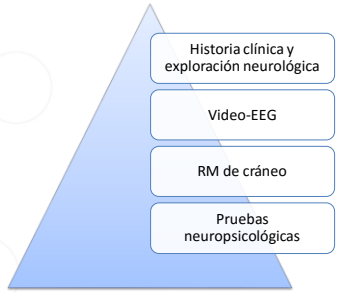

Neurol India, 2002; 50 : 11-16

Fase Invasiva

Indicaciones de Fase Invasiva

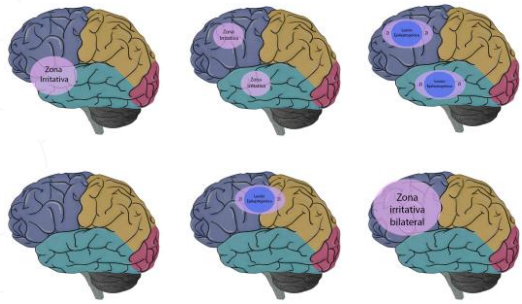

Video-EEG subdural prolongado

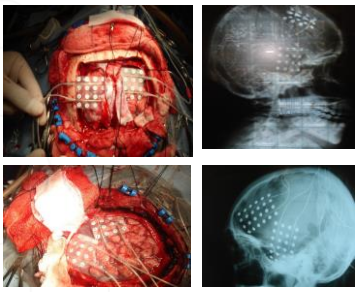

Tiene una mayor sensibilidad para detectar actividad epileptiforme comparado con el EEG de rutina.[1]

[1]Salanova et al., 1993

Mapeo cortical eléctrico

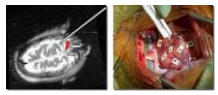



Figure 1.
Timing of verbal command, verbal or visual item presentation, and task performance in relation to cortical current application. The hatched sections indicate the period of current application in relation to the timing of command and item presentation to the patient (both in italics) and the responses of the patient (in bold). In counting (C), Token Test (TT), and body commands (BC), due to early stimulation, language comprehension and output modalities are tested. By starting stimulation only shortly before object presentation, naming (N) does not test language comprehension but isolates the induction of anomia. In reading (Rd) and repeating (Rp), stimulation starts only at either verbal or written language presentation.
Epilepsia © ILAE

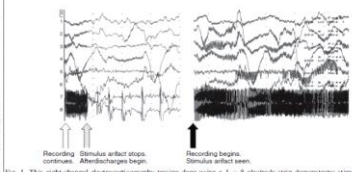

Fig. 1. This eight-channel electrocorticography tracing done using a 1 × 8 electrode strip demonstrates stimulus artifact and afterdischarges. For this recording, the stimulating electrodes were held nearest to electrodes 7 and 8. The recording actually begins near the middle of the display (solid arrow). Stimulus artifact can be seen in all eight channels, with maximum stimulus artifact seen at channels 7 and 8. The recording continues left to right until the far right end of the display and resumes at the far left end of the display (open arrow) where stimulus artifact continues. At the stippled arrow, the stimulus artifact abruptly ceases and afterdischarges are seen at channels 7 and 8. The recording settings for this ECoG are: low-frequency filter 0.5 Hz, high-frequency filter 100 Hz, and sensitivity 200 μV/mm. Bipolar stimulation was administered at a rate of 60 Hz and an intensity of 14 mA.

Wellmer J et al., Epilepsia, 50(10):2267–2275, 2009

Algoritmo de evaluación prequirúrgica de ELF

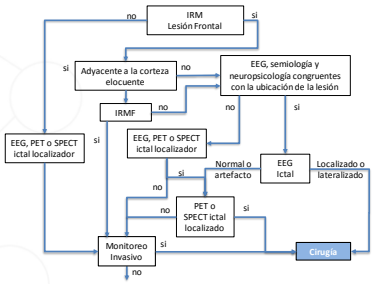

Fig. 4. Algoritmo de investigaciones utilizada en nuestra institución para la evaluación pre-quirúrgica de pacientes con epilepsia del lóbulo frontal.

Modificado de Wellmer J et al., Epilepsia, 50(10):2267–2275, 2009

Retos del proceso de evaluación pre-quirúrgica

- Neuroimagen
  - No existen estudios clase I de IRM en epilepsia (1.5,3.0 o 7.0 T).
  - Realizar estudios diagnósticos con suficientes # de ptes (15-30 y raros >100), aleatorizados y cegados.
  - Desarrollar lineamientos y evaluaciones económicas de la tecnología (P. ej. PET/SPECT).
  - La realización e interpretación de un estudio de medicina nuclear requiere de un especialista y condiciones controladas.

[1]Gaillard W et al., Epilepsia, 52(9):1750–1756, 2011

Retos del proceso de evaluación pre-quirúrgica

- Neurofisiología Clínica
  - Lateralización del lenguaje; Prueba de Wada (estándar de oro); mayor riesgo, limitado tiempo de evaluación, resultados inexactos, razones técnicas y vasculares inducen fallas.[1]
  - Mapeo eléctrico cortical; limitado tiempo de evaluación y zonas restringidas.[1]
  - Falta de acceso a las tecnologías y personal especializado.
  - Estudios comparativos y con mayor # de pacientes de MEG y ESI.[2]

[1]Gaillard W et al., Epilepsia, 52(9):1750–1756, 2011
[2]*Wellmer J et al., Epilepsia, 50(10):2267–2275, 2009*

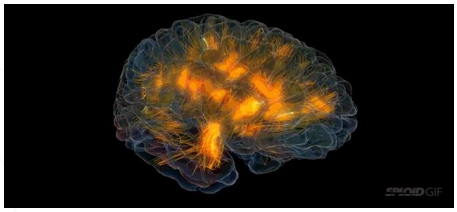

Experiencia local

n:52 pacientes adultos (1999-2009)

Instituto Nacional de Neurología y Neurocirugía Manuel Velasco Suárez

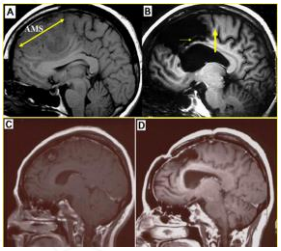

Figura 1. IRM T1 ponderada sagittal de 2 ptes; 1 con un tumor de bajo grado (A-B) y otro con cavernoma (C-D). **A)** IRM prequirúrgica y **B)** IRM post-quirúrgica de un hombre de 36a con un astrocitoma grado I del AMS izquierda **C)** IRM prequirúrgica con Gd y **D)** IRM con Gd postquirúrgicade una mujer de 33a con un cavernoma del AMS izquierda. A 1 año de seguimiento ambos son Engel I. Abreviaturas: AMS: área motora suplementeria, Gd: Gadolinio IRM: Imagen de resonancia magnética

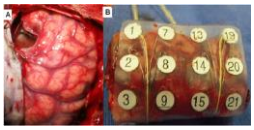

Figura 2. A) Imagen intraoperatoria de la resección completa de la displasia cortical del área motora suplementaria derecha. B) Tejido resecado del AMS con malla de electrodos.

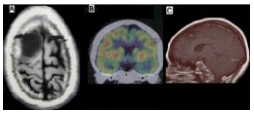

Figura 3. Hallazgos de neuroimagen de ptes con diferentes etiologías de epilepsia del AMS. **A)** IRM T1 ponderada de un astrocitoma derecho grado I, mujer de 40 a. **B)** PET CT con hipometabolismo en el AMS izquierda, 26a hombre con displasia cortical. **C)** y **D)** IRM preoperatoria y postoperatoria de un pte de 32a con un cavernoma derecho del AMS.

Tabla. Hallazgos ictales e interictales en EEG de superficie y video-EEG en 52 pacientes con epilepsia del AMS.

Localización	Actividad epileptiforme	Enlentecimiento focal
Fronto-central derecho	2	1
Fronto-central izquierdo	15	1
Frontal derecho	1	7
Frontal izquierdo	3	11
Fronto-temporal derecho	3	1
Fronto-temporal izquierdo	2	4
Bi-frontal	1	0
Total	27 (52%)	24(48%)



Instituto Nacional de Neurología y Neurocirugía Manuel Velasco Suárez

Figura 4. Resultado quirúrgico de la frecuencia mensual de crisis por etiología: A) Displasia cortical (n=17); B) cavernomas (n=7); C) Tumores de bajo grado (n=28), * $p < 0.05$ con T Student test. Abreviaturas: Pre-Qx: Pre-operatiorio. Post-Qx: Post-operatorio.

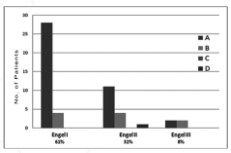

Figura 5. Resultados quirúrgicos en 52 ptes con epilepsia del AMS de acuerdo a la clasificación de Engel: Engel I (n=32); Engel II (n=16); Engel III (n=4).

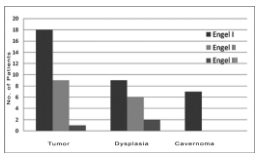

Figura 6. Resultados quirúrgicos de cirugía del AMS por etiología: Tumor (n=28); Displasia cortical (n=18); Cavernoma (n=7), frecuencias.

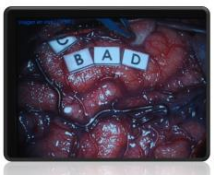

GRACIAS POR SU ATENCIÓN


#AESmtg15
American Epilepsy Society
69TH ANNUAL MEETING DECEMBER 4 - 8, 2015 PHILADELPHIA, PA

CIRUGÍA DEL LÓBULO FRONTAL PARA EPILEPSIA

Arthur Cukiert, MD, PhD

Programa de Cirugía para Epilepsia, Clinica de Epilepsia de São Paulo, São Paulo, Brasil
Departamento de Neurocirugia, Faculdade de Medicina do ABC, Sao Paulo, Brasil

Conflictos de interés:

- Nada a declarar.

Metas de aprendisaje:

- Reconocer los sistemas neuronales múltiplos del lóbulo frontal.
- Verificar la importáncia de la evaluación pre-operatória para el resultado quirúrgico.
- Resúmen de las diferentes técnicas invasivas de monitoreo y resección.

Impacto en los cuidados y en la práctica clínica:

- Reconocer los pacientes con epilepsia del lóbulo frontal refractaria (rFLE) que puedan ser candidatos para cirugía.
- Reconocer los pacientes con rFLE que puedan presentar mejor resultado quirúrgico.
- Estar apto a informar pacientes con rFLE de las diferentes técnicas de monitoreo invasivo y resección cirúgica.
- Estar apto a informar los pacientes con rFLE de las complicaciones cirúgicas.

No un ÚNICO LÓBULO frontal, sinó MÚLTIPLES LÓBULOS frontales.

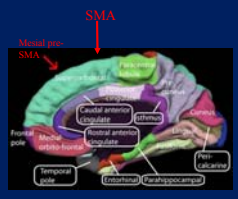

Anatomia funcional del lóbulo frontal y semiología de las crisis:

- Corteza motora: crisis parcial simple motora.
- Corteza opercular dominante (Zona de Broca): afasia.
- Campo frontal visual: desvio ocular y de la cabeza.
- Convexidad lateral: crisis parcial compleja.
- Zona motora suplementar: crisis postural.
- Corteza pré-frontal mesial: crisis hipermotora.
- Fronto-basal: crisis olfatoria.
- Orbito-frontal: crisis parcial compleja.

CIRUGÍA DEL LÓBULO FRONTAL PARA EPILEPSIA

Anatomia funcional del lóbulo frontal y semiología de las crisis:

- Aunque la corteza motora primária sea considerada parte del lóbulo frontal, las zonas motora primária y somato-sensitiva (parietal) deben ser consideradas parte de um lóbulo distinto (lobulo rolandico), en lo que se refiera a la epilepsia.

CIRUGÍA DEL LÓBULO FRONTAL PARA EPILEPSIA

Cirugía no modulatória para Epilepsia (1996-2014)	
Resección temporal	979
Resección frontal	207
Resección rolándica	77
Hemisferectomía	106
Resección del cuadrante posterior	76
Resección parietal	31
Resección occipital	19
Resección insular	8
Callosotomía	214
TOTAL	1701

VNS 117, DBS 37
Grillas 138
Profundidad 11

RESECCIONES EXTRA-TEMPORALES EN EPILEPSIA
RESULTADOS: pacientes sin crisis (%)

	MRI +	MRI -
Frontal	92	66
Rolandica	94	60
Parietal	89	80
Occipital	85	81
Cuadrantectomia posterior	91	77
Hemisferectomia	91	N/A

CIRUGÍA DEL LÓBULO FRONTAL PARA EPILEPSIA

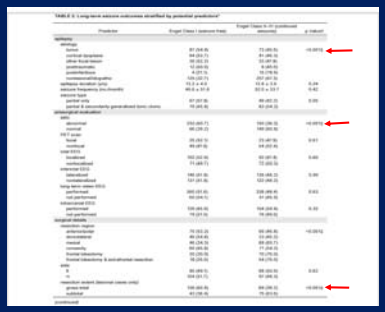

Englot et al
J Neurosurg
2012; 116:1042-48

CIRUGÍA DEL LÓBULO FRONTAL PARA EPILEPSIA

- Pacientes con epilepsia del lóbulo frontal y RM normal, frecuentemente necesitan grandes resecciones.
- Resecciones pequeñas normalmente tienen peores resultados para mejora de las crisis.

CIRUGÍA DEL LÓBULO FRONTAL PARA EPILEPSIA

- El mejor escenário seria ser capaz de resecar la zona de la lesión (cualquiera), la zona ictal inicial, la zona de obtención de las crisis por estimulación y la región interictal.

CIRUGÍA DEL LÓBULO FRONTAL PARA EPILEPSIA

- Si existe lesión epileptogénica (tumoral, vascular, displasia cortical etc), la resección debe incluir toda la lesión.

CIRUGÍA DEL LÓBULO FRONTAL PARA EPILEPSIA

Crisis parciales complejas – Displasia cortical

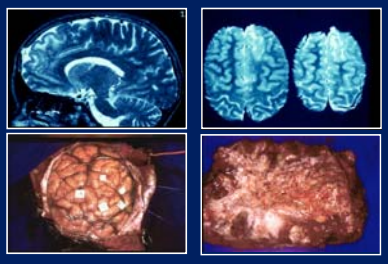

CIRUGÍA DEL LÓBULO FRONTAL PARA EPILEPSIA

Ganglioneuroma – Crisis olfatórias

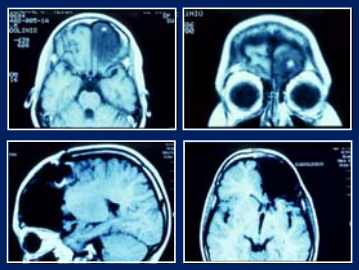

CIRUGÍA DEL LÓBULO FRONTAL PARA EPILEPSIA

Ganglioglioma – Crisis parciales complejas

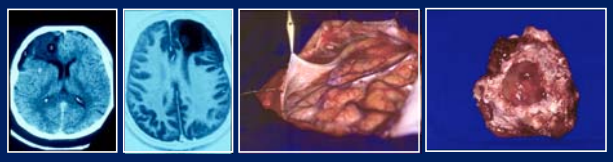

CIRUGÍA DEL LÓBULO FRONTAL PARA EPILEPSIA

Epilepsia pós-traumática – Crisis parciales complejas

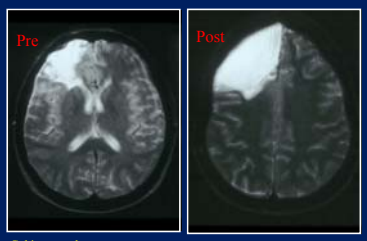

Cukiert et al
Can J Neurol Sci 1996; 23:114-17

CIRUGÍA DEL LÓBULO FRONTAL PARA EPILEPSIA

Displasia cortical – Crisis hipermotoras

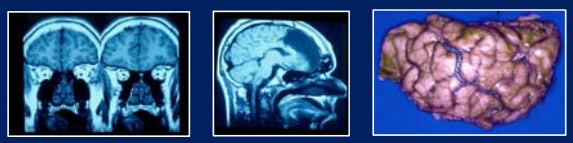

CIRUGÍA DEL LÓBULO FRONTAL PARA EPILEPSIA

Displasia cortical

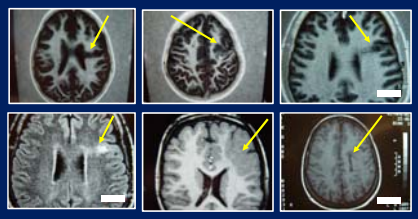

CIRUGÍA DEL LÓBULO FRONTAL PARA EPILEPSIA

Cambios técnicos en la cirugía para Epilepsia

- Disminución del uso de Electrocorticografía;
- Disminución del uso de Craniotomia Despierto;
- Disminución del uso del test com amytal sodico.

CIRUGÍA DEL LÓBULO FRONTAL PARA EPILEPSIA

RESONÁNCIA MAGNÉTICA

- Lesión epileptogénica bién conocida (esclerosis mesial, tumores, displasia, malformaciones vasculares, etc)
  - Cirugia sin video-EEG y sin electrocorticografia intraoperatória (ECoG).
- Sin lesión ó lesión no-específica (atrofia, gliosis, etc)
  - VIDEO-EEG
    - Cirugia sin electrocorticografia intraoperatória. 10%
    - Evaluación invasiva y cirugia sin ECoG 90%

CIRUGÍA DEL LÓBULO FRONTAL PARA EPILEPSIA

- SPECT Interictal
  - No se usa.
- SPECT Ictal
  - Van Paesschen et al. Cur Opin Neurol 2007; 20:194-202
  - Lee et al. Seizure 2008; 17:514-23.
- PET
  - Rathore et al. Epilepsy Res 2014; 108:1306-14.
  - Wang et al. Epilepsia 2013; 54;2195-203.
- MEG
  - Mohamed et al. Epilepsia 2013; 54:1950-59.
  - Kakisaka et al. Epilepsy Res 2012; 102:71-77

CIRUGÍA DEL LÓBULO FRONTAL PARA EPILEPSIA

Electrocorticografia intraoperatória

- Técnica muy limitada;
- Abarca apenas la corteza espuesta por la craniotomia;
- Tiempo corto de registro (30 minutos);
- Apenas registro interictal bajo anestesia.

CIRUGÍA DEL LÓBULO FRONTAL PARA EPILEPSIA

Electrocorticografia intraoperatória

- No hay relación entre la ruptura de la sincronia bilateral secundária durante la cirugía y el resultado en niños sometidos a callosotomia;
- No hay relación entre hallazgos de ECoG intraoperatória y resultados em resecciones del lóbulo temporal;
- En la resección extratemporal, la zona epileptogénica definida por ECoG es casi siempre más grande que la zona adecuada para remoción, basada em datos funcionales (resección maximizada).

CIRUGÍA DEL LÓBULO FRONTAL PARA EPILEPSIA

TABLE 2: Long-term seizure outcomes stratified by potential predictors* *(continued)*

Predictor	Engel Class I (seizure free)	Engel Class II–IV (continued seizures)	p Value†
surgical details *(continued)*			
intraop ECoG			
performed	137 (48.2)	147 (51.8)	0.14
not performed	319 (43.1)	421 (56.9)	
total	541 (45.1)	658 (54.9)	

Englot et al
J Neurosurg
2012; 116:1042-48

CIRUGÍA DEL LÓBULO FRONTAL PARA EPILEPSIA

Craniotomia Despierto

- Muchos pacientes fueron sometidos a anestesia local al princípio de la cirugía para epilepsia. (Penfield, Ojemann)- MUY LIMITADO EN NIÑOS;
- Es sorpreendedor oir que la Craniotomia Despierto es "NUEVA";
- Su utilidad reduciu después de la introducción de nuevas técnicas cirúgicas.

CIRUGÍA DEL LÓBULO FRONTAL PARA EPILEPSIA

Craniotomia Despierto

- Procedimiento muy estresante para el paciente, para el cirujano y para el anestesista;
- El cerebro despierto es menos adecuado para la manipulación cirúgica que el cerebro anestesiado (reactividad vascular);
- La posición de la cabeza debe ser dirigida hacia el mayor comfort del paciente y no del cirujano, de manera que microcirugía no se usa.
- Datos reunidos durante procedimientos con el paciente despierto son obtenidos de manera más confortable con electrodos invasivos cronicamente implantados o mapeo intraoperatorio bajo anestesia.

CIRUGÍA DEL LÓBULO FRONTAL PARA EPILEPSIA

Escaparse de la Craniotomia Despierto

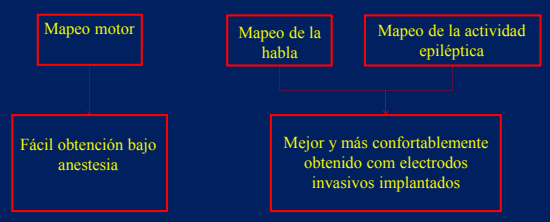

CIRUGÍA DEL LÓBULO FRONTAL PARA EPILEPSIA

Mapeo motor bajo anestesia general

- Remoción de los agentes paralizadores del músculo;
- Estimulación usando pulsos cuadrados (4 a 10mA, 100 Hz y 0.3 mseg);
- Fácil y rápido: 10 minutos (máximo);
- Por lo general, de acuerdo con hallazgos anatómicos, en pacientes sin lesiones con efecto de masa.

CIRUGÍA DEL LÓBULO FRONTAL PARA EPILEPSIA

DNET – crisis motoras suplementarias

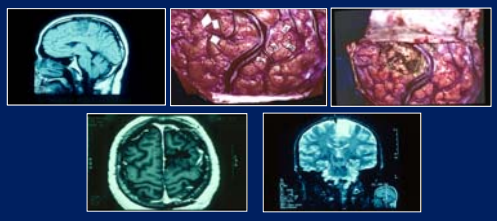

CIRUGÍA DEL LÓBULO FRONTAL PARA EPILEPSIA

Sin lesión

- La mayoría de los pacientes con RM normal y sospecha de epilepsia del lóbulo frontal necesita monitoreo invasivo!

CIRUGÍA DEL LÓBULO FRONTAL PARA EPILEPSIA

Sin lesión: monitoreo invasivo

Profundo

- Baja morbilidad
- Mapeo funcional pobre
- Baja cobertura contigua
- Três procedimientos
- Bueno para sítios profundos(ej: insula)

Grilla

- Más alta morbilidad
- Mapeo funcional bueno
- Buena cobertura contigua
- Dos procedimientos
- Bueno para superficies

CIRUGÍA DEL LÓBULO FRONTAL PARA EPILEPSIA

Paradigmas para la implantación de electrodos subdurales

Síndromes epilépticas

- Bitemporal
- Bifronto-mesial
- Hemisférica
- Cuadrante anterior
- Cuadrante posterior

Cukiert et al
Epilepsia 2001; 42:889-94

CIRUGÍA DEL LÓBULO FRONTAL PARA EPILEPSIA

Paradigmas para la implantación de electrodos subdurales

Síndrome Bi-fronto mesial

- Crisis parciales complejas, crisis hipermotoras, crisis motoras suplementarias.
- Regiones ictal e interictal no localizadas por EEG.
- RM normal.

CIRUGÍA DEL LÓBULO FRONTAL PARA EPILEPSIA

Paradigmas para la implantación de electrodos subdurales

Síndrome Bi-fronto mesial

- Craniotomia bi-frontal.
- Una grilla com 64 contactos sobre la convexidad frontal.
- Una grilla com 16 contactos sobre la superficie mesial (de cada lado).

CIRUGÍA DEL LÓBULO FRONTAL PARA EPILEPSIA

Crisis parciales complejas; crisis posturales asimétricas; descargas interictales frontales independientes + sincronia bilateral secundária, crisis no localizadas y no lateralizadas por video-EEG, RM normal.

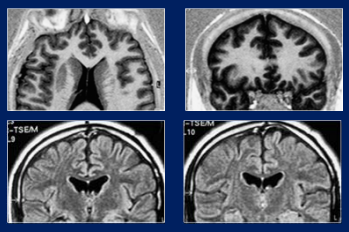

CIRUGÍA DEL LÓBULO FRONTAL PARA EPILEPSIA

Crisis parciales complejas; crisis posturales asimétricas; descargas interictales frontales independientes + sincronia bilateral secundária, crisis no localizadas y no lateralizadas por video-EEG, RM normal.

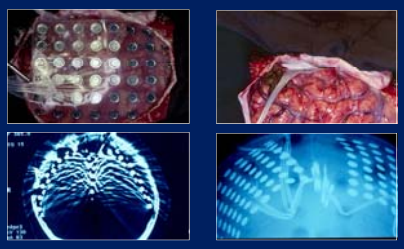

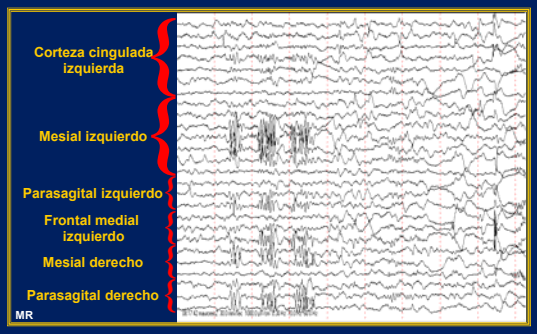

CIRUGÍA DEL LÓBULO FRONTAL PARA EPILEPSIA

Crisis de la area motora suplementaria

Surco central
Interictal
Ictal
Crisis inducida

Electrodos mesial y de convexidad yzquierdos

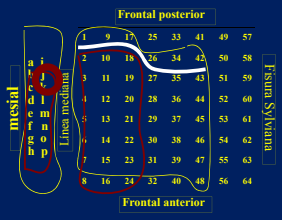

27- Version de la cabeza
29- Área de Broca
c- Extensión de la pierna izquierda y ombro
e- Extensión del brazo derecho
j- Postura tónica de pierna derecha
k- Postura asimétrica:
Flexión del brazo derecho,
Extensión del brazo izquierdo
l- Flexión tónica de la mano derecha

CIRUGÍA DEL LÓBULO FRONTAL PARA EPILEPSIA

Crisis parciales complejas; crisis posturales asimétricas; descargas interictales frontales independientes + sincronia bilateral secundária, crisis no localizadas y no lateralizadas por video-EEG, RM normal.

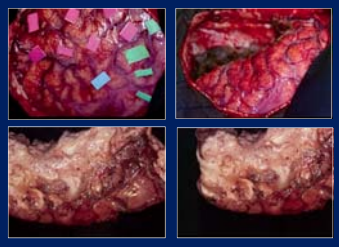

CIRUGÍA DEL LÓBULO FRONTAL PARA EPILEPSIA

Crisis parciales complejas; crisis posturales asimétricas; descargas interictales frontales independientes + sincronia bilateral secundária, crisis no localizadas y no lateralizadas por video-EEG, RM normal.

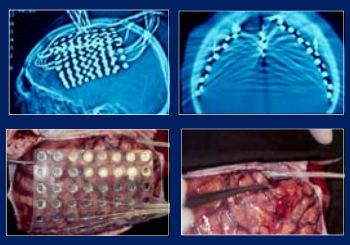

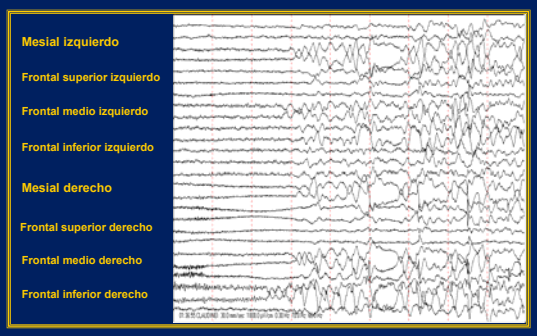

CIRUGÍA DEL LÓBULO FRONTAL PARA EPILEPSIA

Crisis parciales complejas; crisis posturales asimétricas; descargas interictales frontales independientes + sincronia bilateral secundária, crisis no localizadas y no lateralizadas por video-EEG, RM normal.

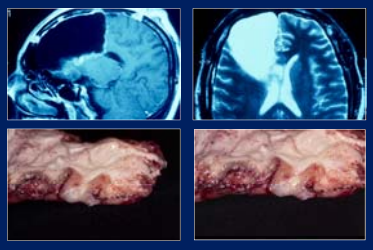

CIRUGÍA DEL LÓBULO FRONTAL PARA EPILEPSIA

Paradigmas para la implantación subdural de electrodos

Síndrome Hemisferico

- Padrón de crisis múltiplas.
- EEG muestra espigas interictales multifocales com pequeña sincronia bilateral secundária.
- Registros ictales no-localizados.
- RM normal ó com atrofia difusa.

CIRUGÍA DEL LÓBULO FRONTAL PARA EPILEPSIA

Paradigmas para la implantación subdural de electrodos

Síndrome Hemisferico

- Craniotomia hemisférica.
- Una grilla com 64 contactos y una com 34 contactos.

CIRUGÍA DEL LÓBULO FRONTAL PARA EPILEPSIA

Crisis parciales simples motoras a la derecha (brazo-pierna-cara); espigas interictales multifocales yzquierdas; video-EEG no localizado, RM normal.

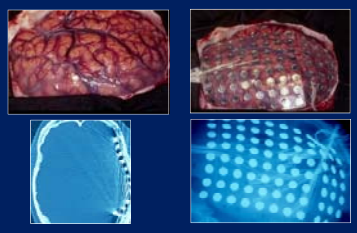

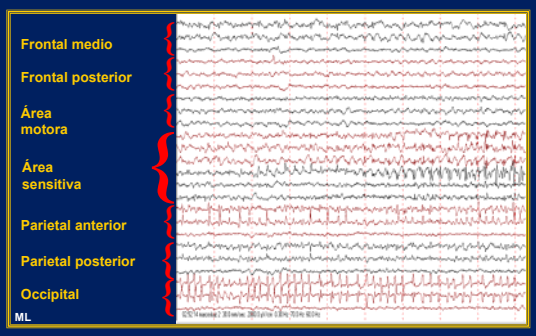

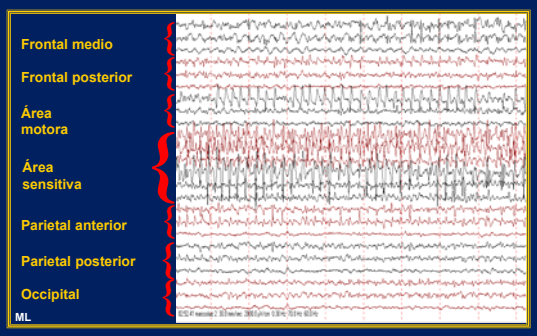

CIRUGÍA DEL LÓBULO FRONTAL PARA EPILEPSIA

Crisis parciales simples motoras a la derecha (cara); espigas interictales multifocales a la izquierda; crisis no localizadas por video-EEG; RM normal.

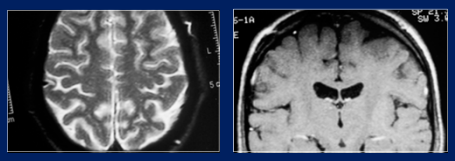

CIRUGÍA DEL LÓBULO FRONTAL PARA EPILEPSIA

Crisis parciales simples motoras a la derecha (cara); espigas interictales multifocales a la izquierda; crisis no localizadas por video-EEG; RM normal.

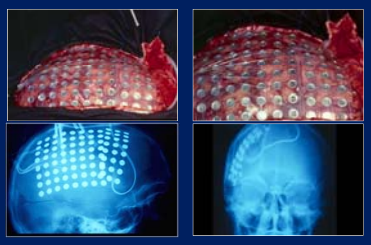

CIRUGÍA DEL LÓBULO FRONTAL PARA EPILEPSIA

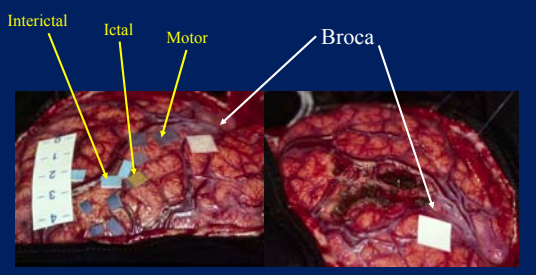

CIRUGÍA DEL LÓBULO FRONTAL PARA EPILEPSIA

Crisis parciales simples motoras a la derecha (cara); espigas interictales multifocales a la izquierda; crisis no localizadas por video-EEG; RM normal.

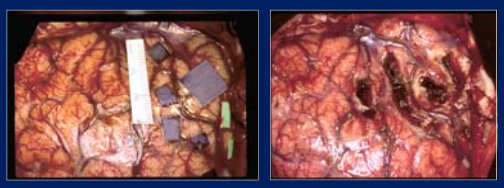

CIRUGÍA DEL LÓBULO FRONTAL PARA EPILEPSIA

Crisis posturales reflejas del pié izquierdo, EEG interictal normal, EEG ictal no lozalizado, RM normal.

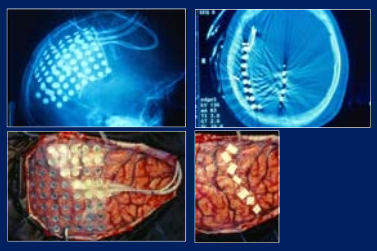

CIRUGÍA DEL LÓBULO FRONTAL PARA EPILEPSIA

Crisis reflejas del pié

Hemisfério derecho

CIRUGÍA DEL LÓBULO FRONTAL PARA EPILEPSIA

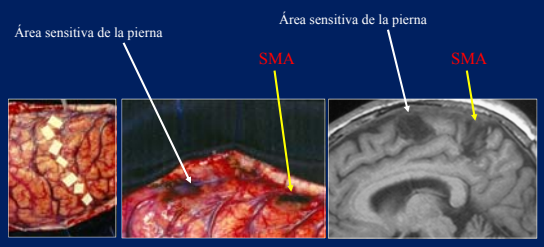

CIRUGÍA DEL LÓBULO FRONTAL PARA EPILEPSIA

- La resección cortical puede ser hecha de manera segura en la corteza motora de las áreas de la lengua y rostro.
- La resección cortical completa de la circunvolución sensitiva puede ser hecha sin gran morbilidad a largo plazo.

CIRUGÍA DEL LÓBULO FRONTAL PARA EPILEPSIA

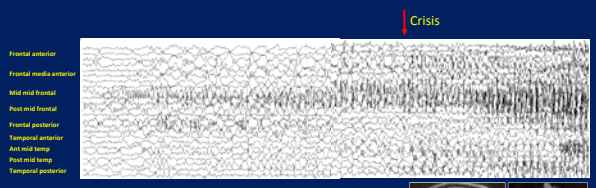

Crisis parciales complejas, espigas frontales y temporales independientes a la yzquierda infrecuentes, registros ictales no localizados, RM normal.

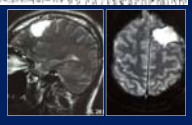

CIRUGÍA DEL LÓBULO FRONTAL PARA EPILEPSIA

Paradigmas para la implantación subdural de electrodos

Síndrome del Cuadrante Anterior

- Crisis múltiples.
- EEG interictal e ictal no localizados;
- Padrón convulsivo sugestivo de início en el cuadrante anterior.
- RM normal ó atrofia difusa.

CIRUGÍA DEL LÓBULO FRONTAL PARA EPILEPSIA

Paradigmas para la implantación subdural de electrodos

Síndrome del Cuadrante Anterior

- Craniotomia fronto-temporo-parietal.
- Una grilla con 64 contactos sobre el lóbulo frontal y temporal.
- Una grilla con 16 contactos sobre la zona mesial.

CIRUGÍA DEL LÓBULO FRONTAL PARA EPILEPSIA

Crisis parciales complejas, espigas difusas y frontales a la derecha, EEG ictal no localizado, RM normal (excepto para calcificación secuelar).

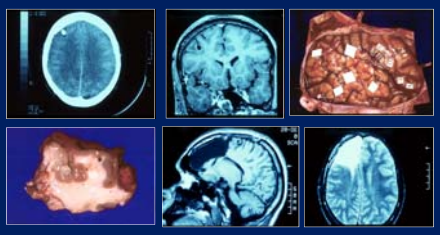

CIRUGÍA DEL LÓBULO FRONTAL PARA EPILEPSIA

Crisis de la área motora suplementar, espigas interictales difusas a la izquierda, EEG ictal no localizado, atrofia difusa del hemisfério izquierdo en la RM, y sin déficit motor.

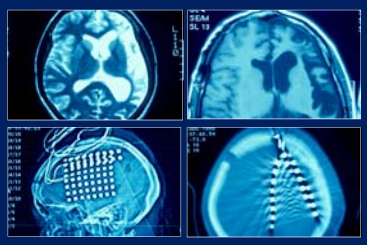

CIRUGÍA DEL LÓBULO FRONTAL PARA EPILEPSIA

Crisis de la área motora suplementar, espigas interictales difusas a la izquierda, EEG ictal no localizado, atrofia difusa del hemisfério izquierdo en la RM, y sin déficit motor.

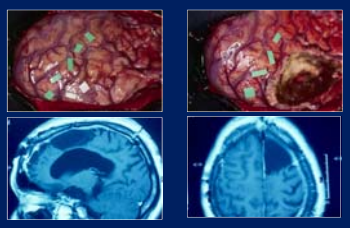

CIRUGÍA DEL LÓBULO FRONTAL PARA EPILEPSIA

COMPLICACIONES

- Esperadas: hemiparesia, distúrbios de lenguaje, meningitis asséptica, etc.
- Inesperadas...

CIRUGÍA DEL LÓBULO FRONTAL PARA EPILEPSIA

COMPLICACIONES INESPERADAS (n=1063; resecciones extra-temporales)

- Hematoma extra dural sintomático (n=3);
- Infección del flap (hueso manipulado) (n=4);
- Meningitis (n=1);
- Infarto a la distáncia en el tallo encefálico con tetraparesia (n=1);
- Hemorragia cerebelar (n=5);
- Muerte (n=4; 1 muerte súbita; 1 hipertermia maligna, 1 síndrome de la acidosis maligna del propofol, 1 síndrome visceral maligna de la fenitoína).

GRACIAS!!

AMERICAN EPILEPSY SOCIETY

69TH ANNUAL MEETING DECEMBER 4 - 8, 2015 PHILADELPHIA, PA

#AESmtg15

AMERICAN EPILEPSY SOCIETY

69TH ANNUAL MEETING DECEMBER 4 - 8, 2015 PHILADELPHIA, PA